

Zeitschrift: Acta Tropica
Herausgeber: Schweizerisches Tropeninstitut (Basel)
Band: 41 (1984)
Heft: 2

Artikel: "Mycobacterium ulcerans" in Liberia : a clinicopathologic study of 6 patients with Buruli ulcer
Autor: Monson, M.H. / Gibson, D.W. / Connor, D.H.
DOI: <https://doi.org/10.5169/seals-313291>

Nutzungsbedingungen

Die ETH-Bibliothek ist die Anbieterin der digitalisierten Zeitschriften. Sie besitzt keine Urheberrechte an den Zeitschriften und ist nicht verantwortlich für deren Inhalte. Die Rechte liegen in der Regel bei den Herausgebern beziehungsweise den externen Rechteinhabern. [Siehe Rechtliche Hinweise.](#)

Conditions d'utilisation

L'ETH Library est le fournisseur des revues numérisées. Elle ne détient aucun droit d'auteur sur les revues et n'est pas responsable de leur contenu. En règle générale, les droits sont détenus par les éditeurs ou les détenteurs de droits externes. [Voir Informations légales.](#)

Terms of use

The ETH Library is the provider of the digitised journals. It does not own any copyrights to the journals and is not responsible for their content. The rights usually lie with the publishers or the external rights holders. [See Legal notice.](#)

Download PDF: 15.03.2025

ETH-Bibliothek Zürich, E-Periodica, <https://www.e-periodica.ch>

¹ Curran Lutheran Hospital, Box 1046, Monrovia, Liberia, West Africa

² Department of Infectious and Parasitic Disease Pathology,
Armed Forces Institute of Pathology, Washington, D.C. 20306, USA

³ Bong Mine Medical Center, Box 538, Monrovia, Liberia, West Africa

⁴ Institut für Pathologie, Städtische Krankenanstalten Krefeld, Lutherplatz 40,
4150 Krefeld 1, West Germany

***Mycobacterium ulcerans* in Liberia: a clinicopathologic study of 6 patients with Buruli ulcer**

M. H. MONSON¹, D. W. GIBSON², D. H. CONNOR², R. KAPPES³, H. A. HIENZ⁴

Summary

Two patients with Buruli ulcer (infection by *Mycobacterium ulcerans*) in the Foya region of Liberia have recently been reported. We describe three more patients which together with the two original patients establish the Mayor River basin as an endemic area of Buruli ulcer. We also describe a patient from the St. Paul River basin. This disease, unrecognized in Liberia before 1978, now seems to be widespread in Liberia and has been reported in neighboring Sierra Leone and observed in Ivory Coast as well. The possibility of Buruli ulcer appearing in other regions of West Africa should be anticipated. Diagnosis involves finding acid-fast bacilli in smears of the exudate from typical lesions or by finding in biopsy specimens the characteristic zone of coagulation necrosis containing acid-fast bacilli. The bacillus, *Mycobacterium ulcerans*, stains readily with the Ziehl-Neelsen (ZN) and Fite-Faraco (FF) procedures. Treatment is excision when the lesion is small and by debridement and grafting, combined with heat and chemotherapeutic agents when the lesion is large.

Key words: *Mycobacterium ulcerans*; Buruli ulcer; Liberia.

Introduction

Buruli ulcers are infections caused by *Mycobacterium ulcerans*, an acid-fast bacillus (AFB) that grows preferentially at 33°C (MacCallum et al., 1948; Connor and Lunn, 1966; Connor et al., 1976). The term Buruli comes from the

Correspondence: Dr. D. H. Connor, Department of Infectious and Parasitic Disease Pathology, Armed Forces Institute of Pathology, Washington, D.C. 20306, USA

Buruli District of Uganda, near Lake Victoria, where the disease was first described (Cook, 1897). Young people are most susceptible. Preulcerative infections and small ulcers can be cured by complete excision. Large ulcers may intimidate the clinicians but wide debridement and grafting is surprisingly helpful. If patients go untreated, the natural tendency is to heal – but only after months or years of chronic ulceration. Buruli ulcer can be confirmed by smear, culture or biopsy, and smears demonstrating AFB are most easily done in rural hospitals. The exudate from the deepest recesses is most likely to contain AFB. They are extracellular, usually in clusters and stain with the ZN procedure. Biopsy specimens of Buruli ulcers show a characteristic histopathologic pattern, with undermining of the edge and coagulation necrosis of adipose tissue.

Endemic areas tend to be sparsely populated swampy lowlands and river valleys. The disease has been reported in Cameroon, Congo, Gabon, Ghana, Nigeria, Uganda, Zaire, and probably also Angola and Mozambique (Connor and Lunn, 1966; Connor et al., 1976; Gray et al., 1967; Meyers et al., 1974).

Foya, a trading and agricultural town in northern Liberia ($8^{\circ}21'N \times 10^{\circ}12'W$) stands on the Mayor River 250 km north of Monrovia (Fig. 1a, b). Two patients from Foya, previously described (Ziefer et al., 1981), were thought to be westernmost in Africa; but we now know of three patients in Sierra Leone – about 175 km west of Foya (Gibson, 1975). In addition we have recently heard of several characteristic Buruli ulcers in west-central Ivory Coast – about 300 km southeast of Foya (personal communication, Dr. Keith Beck, Harbor-UCLA Medical Center, California, USA). Here we present data on six Liberians with Buruli ulcer (Table 1): two previously reported from Foya (Ziefer et al., 1981), three more from the Foya region, and one from Haindii ($60^{\circ}53'N \times 10^{\circ}24'W$) on the St. Paul River about 150 km south of Foya (Fig. 1a).

Case reports (see Table 1 and Fig. 1a, b)

Patient 1 came to SFPMC in late 1978 with a 5×4 -cm painless ulcer on the lateral aspect of the right knee. It had been present for many months, had undermined edges, a foul odor and had caused flexion contracture of the knee. A biopsy specimen taken in December 1978 revealed typical findings of *M. ulcerans* infection including AFB in the biopsy specimen and in smears. The patient was referred to Curran Lutheran Hospital (CLH) in Zorzor, 110 km southeast of Foya. Debridement was done and some healing followed; but in March, 1979, a new ulcer began in the left inguinal region. His father took him to Guinea for “traditional treatment”, where he has remained. Family members in Liberia report (in 1982) that he is alive and that his ulcers have healed.

Patient 2 came to CLH in 1977 with an ulcer on his right arm. Shortly after transferring to SFPMC in October 1978 he developed a new ulcer on his right foot about 3 cm in diameter. This ulcer had undermined edges and a biopsy specimen at SFPMC in December 1978 revealed characteristic changes of Buruli ulcer and AFB. When the patient was referred back to CLH for debridement his father refused to take him back to CLH, but arranged instead for “traditional treatment”. He has not been heard from since.

Patient 3 came to SFPMC in June, 1981 with a 10×5 -cm painless ulcer of long duration on the right arm about the elbow. There was also a 1-cm “satellite” ulcer (Fig. 2). Both were undermined.

Table 1. Clinical and pathological observations on 6 Liberian patients with Buruli ulcer (*M. ulcerans*)

Patient No.	Age (yr). sex	Home village ^a (river basin)	Buruli ulcer		Diagnosis ^b	Treatment	Outcome
			Site(s)	Size			
1 ^c	8. ♂	Fasapo ^c (Mayor)	right knee	5 × 4 cm ("new")	AFP in smears and biopsy clinical appearance	debridement "traditional"	"healed"
2 ^d	11. ♂	Leobengu ^d (Mayor)	right arm right foot	5 × 3 cm 3 × 3 cm	clinical appearance AFB in biopsy	(previous spontaneous "healing") ^d "traditional" (lost to follow-up)	"healed"
3	10. ♂	Bassor (Mayor)	right elbow (+ "satellite" @	10 × 5 cm 1 × 1 cm. Fig. 2)	AFB in smear AFB in smear (Fig. 3)	(dressings only) (left hospital)	persisted
4	12. ♀	Kpello (Mayor)	left elbow	2 × 2 cm	AFB in smear	debridement	"healed"
5	19. ♀	Hundoning (Mayor)	left arm, elbow, axilla and breast	"extensive"	characteristic clinical appearance	wide debridements, grafting and dressings	partially "healed"
6	1½. ♀	Haindii (St. Paul)	left leg	1 × 1 cm	characteristic clinical appearance	Furacine, Ampicillin, Lincocyn. excision	"healed"

^a see Fig. 1a, b for maps showing the 6 villages, in the Mayor River and St. Paul River basins

^b AFB = acid-fast bacilli (Ziehl-Neelsen stain); biopsy = wedge biopsy specimen of skin through ulcer margin

^c also patient 1 in Ziefer et al., 1981; village corrected; follow-up on new inguinal ulcer (see text)

^d also patient 2 in Ziefer et al., 1981; village corrected; follow-up on "traditional treatment" (see text)

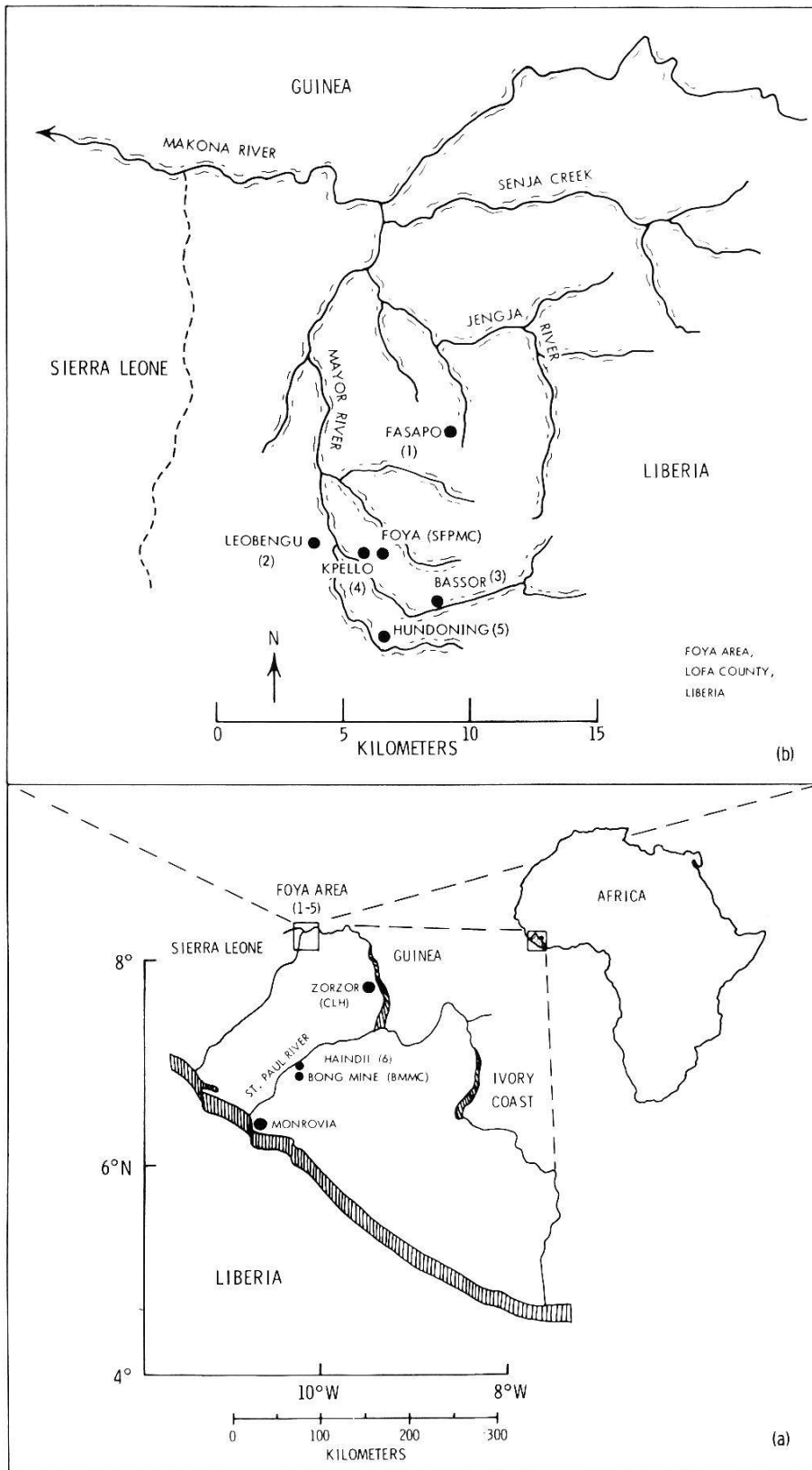


Fig. 1. (a) Map of Liberia, showing Monrovia (capital); the Foya region (inset; see b); Zorzor (Curran Lutheran Hospital, CLH); the St. Paul River; Bong Mine Medical Center (BMMC); and Haindii, the village of patient 6. (b) Map of the Mayor River basin near Foya (inset from a), showing the Swedish Free Pentecostal Mission Clinic (SFPMC) at Foya, and the villages of patients 1–5 (AFIP Neg. 83-6143).

Dressings produced no healing so he was referred to CLH where a smear of the exudate contained clusters of AFB (Fig. 3). After a short time, in spite of no healing his family took him back to Bassor. He was seen by a nurse in his home in April 1982, still active and apparently not bothered much by the persistent ulcer.

Patient 4 came to SFPMC in December, 1981 with a 2-cm painless ulcer over the left olecranon. There was brawny swelling but no limitation of motion. She was referred to CLH where initial smears for AFB were negative. She was then treated for cellulitis without response. The ulcer was then debrided widely and found to extend over the entire elbow. After debridement smears contained many AFB. She was referred for medical care in Monrovia where her ulcer healed.

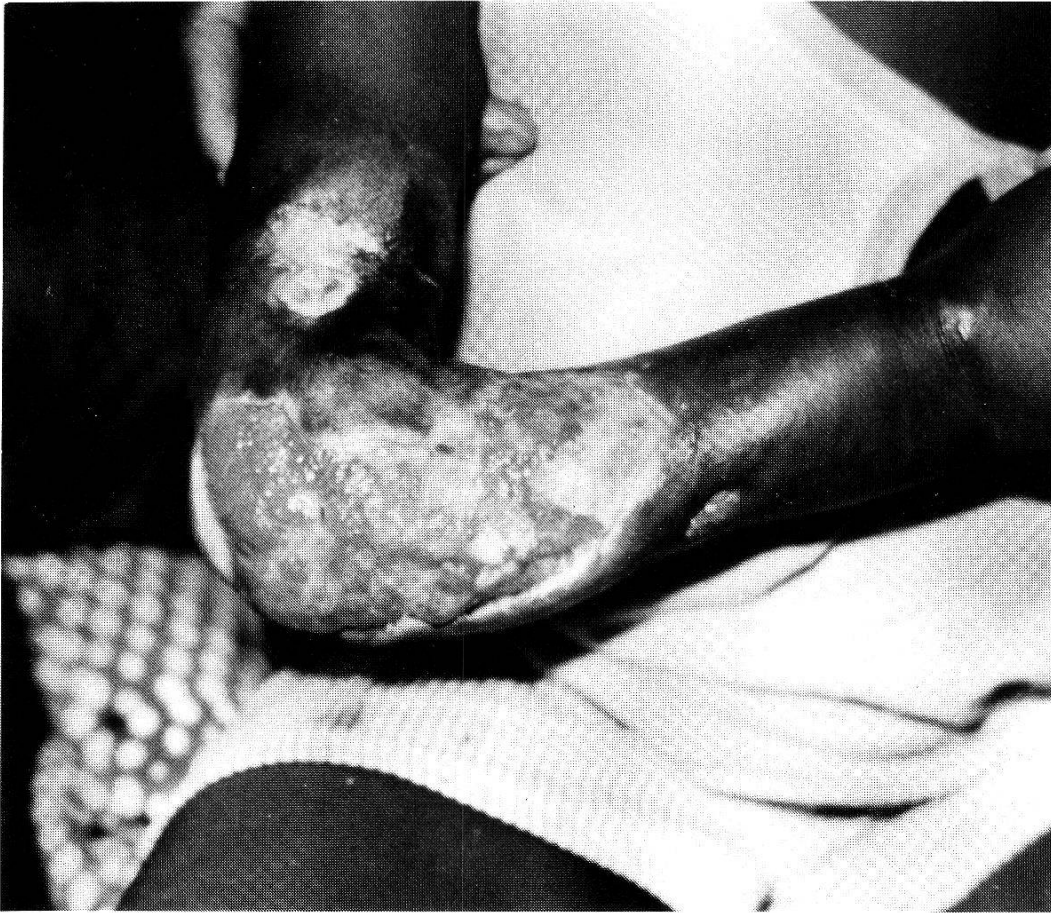Patient 5 first came to SFPMC in May 1981, with an extensive painless ulcer on the left arm. It had undermined edges and she was referred to CLH where the ulcer expanded rapidly from below the elbow, encircling the arm except for a 3-cm strip on the medial side. The undermining extended into the axilla, and into the tail of the left breast. She had a flexion contracture of the elbow. No attempt was made to demonstrate AFB but her lesion was characteristic. After a protracted hospital course including multiple wide debridements, grafting, dressings, and an incidental Caesarian section for a healthy infant, she returned 10 months later to SFPMC for dressings. The only remaining open area was the axilla and tail of the breast. She failed to return for dressings and on her last visit the ulcer bed contained maggots and was expanding. She died in 1982, of undetermined cause.

Patient 6 came to BMCM in November, 1980. About 4 weeks before admission she developed a "boil" on the lateral aspect of the left leg. This ruptured and the patient was brought to the first aid station. The ulcer was dressed with Furacine ointment for 14 days, then excised. The patient was also treated with Ampicillin and later Lincocyn for 2 weeks before excision. The ulcer did not improve with these treatments and was about 1 cm across and widely undermined. After excision the wound healed without complication. Histopathologic studies revealed coagulation necrosis of fat in the margin of the ulcer bed and extensive granulomatous panniculitis beyond. A thorough search for AFB failed to reveal organisms. The patient was seen again in February, 1983 (2½ years later), and the ulcer remained healed.

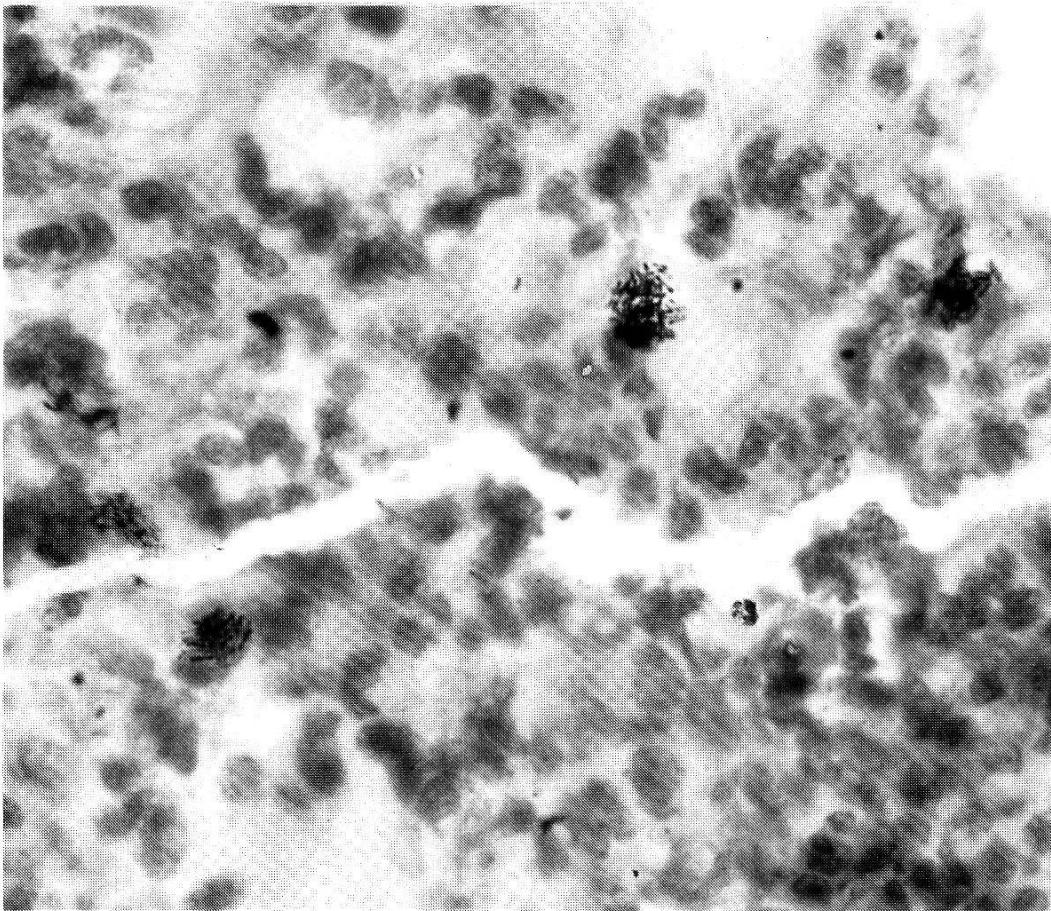
Discussion

The first five patients come from a 6-km radius around Foya. Their villages have been located and confirmed (Table 1, Fig. 1b), with changes from those cited earlier for patients 1 and 2 (Ziefer et al., 1981). The native Kisi have traditionally farmed rice in swamps, in contrast to the uplands rice farmed by neighboring tribes. Cultivation of swamp rice has been promoted to improve yield and the Kisi have readily accepted this. Construction of dams on the Mayor River near Foya has also promoted swamp rice farming. Each patient's village is on the banks of the Mayor River or its tributaries (Fig. 1b). Interestingly, the literal translation of Hundoning (village of patient 5) is "in the swamp". This village sits on a hill surrounded by swamp. These additional patients with Buruli ulcer from the Mayor River basin establish this as an endemic area. Swamp rice farming there may have promoted infection.

Recently (September, 1983) CLH admitted a 19-year-old male patient who has an extremely large ulcer extending to the trochanter of the femor bilaterally, and laterally to the iliac crest. The clinical appearance is characteristic of a Buruli ulcer. This patient works in a swamp at Konkisi, near Boya on the Liberia-Sierra Leone border, in the Makona River basin and 15 km southwest of Foya.



2



3

Patient 6 comes from a village on the St. Paul River, 150 km south of Foya. This is a large river that enters the Atlantic Ocean just north of Monrovia (Fig. 1a). Swamps and rice farming are near the village. AFB were not found in patient 6, but the chronicity of this ulcer, its location on a limb, the undermining, and the coagulation necrosis of adipose tissue are all consistent with Buruli ulcer. The extensive granulomatous panniculitis indicates resolution and this may explain the lack of AFB. The ulcer of patient 6 prompted the staff at BMMC and they recalled similar lesions of other patients. During March, 1983 a 25-year-old female patient there had a large ulcer of the right lower leg with the characteristic appearance of Buruli ulcer. These two or more patients at BMMC indicate that this portion of the St. Paul River basin is an endemic area for Buruli ulcer, about 150 km from the Mayor River basin.

Our studies indicate that Buruli ulcer is more common and more widely distributed in Liberia and neighboring countries than previously suspected. Patients with Buruli ulcer appear to live in a wide band in West Africa roughly 100 to 300 km inland. Further studies and case reports will define the endemic area more precisely.

Acknowledgments

This work was supported in part by the Division for World Mission and Ecumenism, Lutheran Church in America, New York, USA, and in part by the World Health Organization, Geneva, Switzerland. The staff of the Swedish Free Pentecostal Mission Clinic in Foya, Liberia helped locate and treat patients 1–5. J. Buck, D. Dorborson, and the laboratory staff at Curran Lutheran Hospital in Zorzor, Liberia identified acid-fast bacilli on the smears of patients 3 and 4.

The opinions or assertions contained herein are the private views of the authors and are not to be construed as official or as reflecting the views of the Department of the Army or the Department of Defense, the sponsoring institutions, or the institutions with which the authors are affiliated.

Connor D. H., Lunn H. F.: Buruli ulceration. A clinicopathologic study of 38 Ugandans with *Mycobacterium ulcerans*. Arch. Path. (Chicago) 81, 183–199 (1966).

Connor D. H., Meyers W. M., Krieg R. E.: Infection by *Mycobacterium ulcerans*. In: Pathology of tropical and extraordinary diseases, ed. by C. H. Binford and D. H. Connor, Vol. 1, p. 226–235. Armed Forces Institute of Pathology, Washington, D.C. 1976.

Cook A.: The Mengo Hospital notes for the year 1897. Makerere College Medical School Library, Kampala, Uganda 1897.

Gibson J.: Buruli ulcers in Bo. Bull. Sierra Leone med. dent. Ass. 2, 64–66 (1975).

Gray H. H., Kingman S., Kok S. H.: Mycobacterial skin ulcers in Nigeria. Trans. roy. Soc. trop. Med. Hyg. 61, 712–714 (1967).

MacCallum P., Tolhurst Y. C., Buckle G., Sissons H. A.: A new mycobacterial infection in man. J. Path. 60, 93–122 (1948).

Fig. 2. Large Buruli ulcer on elbow of patient 3, with smaller satellite ulcer proximal to main ulcer; on admission to CLH (AFIP Neg. 81-18183).

Fig. 3. Extracellular acid-fast bacilli (*Mycobacterium ulcerans*), in smear from the larger Buruli ulcer of patient 3 (Fig. 2) (Ziehl-Neelsen, $\times 290$; AFIP Neg. 82-11250).

- Meyers W. M., Connor D. H., McCullough B., Bourland J., Moris R., Proos L.: Distribution of *Mycobacterium ulcerans* infections in Zaire, including the report of new foci. *Ann. Soc. belge Méd. trop.* 54, 147–157 (1974).
- Meyers W. W., Shelly W. M., Connor D. H.: Human *Mycobacterium ulcerans* infections developing at sites of trauma to skin. *Amer. J. trop. Med. Hyg.* 23, 919–923 (1974).
- Ziefer A., Connor D. H., Gibson D. W.: *Mycobacterium ulcerans*: infection of two patients in Liberia. *Int. J. Derm.* 20, 362–367 (1981).