

Zeitschrift: Acta Tropica
Herausgeber: Schweizerisches Tropeninstitut (Basel)
Band: 41 (1984)
Heft: 3

Artikel: Cerebral trypanosomiasis in cattle with mixed "Trypanosoma congolense" and "T. brucei brucei" infections
Autor: Masake, Rachel A. / Nantulya, V.M. / Akol, G.W.O.
DOI: <https://doi.org/10.5169/seals-313297>

Nutzungsbedingungen

Die ETH-Bibliothek ist die Anbieterin der digitalisierten Zeitschriften. Sie besitzt keine Urheberrechte an den Zeitschriften und ist nicht verantwortlich für deren Inhalte. Die Rechte liegen in der Regel bei den Herausgebern beziehungsweise den externen Rechteinhabern. [Siehe Rechtliche Hinweise.](#)

Conditions d'utilisation

L'ETH Library est le fournisseur des revues numérisées. Elle ne détient aucun droit d'auteur sur les revues et n'est pas responsable de leur contenu. En règle générale, les droits sont détenus par les éditeurs ou les détenteurs de droits externes. [Voir Informations légales.](#)

Terms of use

The ETH Library is the provider of the digitised journals. It does not own any copyrights to the journals and is not responsible for their content. The rights usually lie with the publishers or the external rights holders. [See Legal notice.](#)

Download PDF: 16.03.2025

ETH-Bibliothek Zürich, E-Periodica, <https://www.e-periodica.ch>

International Laboratory for Research on Animal Diseases (ILRAD), P.O. Box 30709, Nairobi, Kenya

Cerebral trypanosomiasis in cattle with mixed *Trypanosoma congolense* and *T. brucei brucei* infections

RACHEL A. MASAKE, V. M. NANTULYA, G. W. O. AKOL, A. J. MUSOKE

Summary

Six Boran steers were infected simultaneously with *Trypanosoma congolense* and *T. brucei brucei* while another group of 3 was inoculated with *T. b. brucei* one year after infection with *T. congolense*. Three further steers were infected with *T. b. brucei* alone. Whereas, the six animals which received simultaneous infections developed clinical signs of cerebral trypanosomiasis as evidenced by depression, ataxia and occasional circling, those infected with *T. b. brucei* alone did not. At necropsy, 4 out of the 6 simultaneously infected animals had a mild to severe disseminated non-suppurative meningoencephalitis. *Trypanosoma b. brucei* was isolated from the cerebrospinal fluid (CSF) of three out of the four animals with histological lesions. Two of the cattle superinfected with *T. b. brucei* one year after infection with *T. congolense* also developed both clinical and histological evidence of cerebral trypanosomiasis. *Trypanosoma congolense* was isolated from the CSF of one of these 2 animals. Specific antibodies to the variable surface glycoproteins (VSGs) of the infecting *T. b. brucei* and *T. congolense* clones were found in the CSF of the 8 animals that developed cerebral trypanosomiasis. In these animals however, there was neither temporal nor quantitative correlation between VSG-specific antibodies in serum and in CSF, implying a de novo synthesis of antibodies to the infecting trypanosomes in the CSF.

Key words: cattle; mixed infection; *T. b. brucei*; *T. congolense*; cerebral trypanosomiasis.

Correspondence: Rachel A. Masake, Ph.D., International Laboratory for Research on Animal Diseases, P.O. Box 30709, Nairobi, Kenya

Introduction

Clinical cerebral trypanosomiasis is a common occurrence in humans following infection with *Trypanosoma brucei rhodesiense* or *T. b. gambiense* (Mott, 1907; Manuelidis et al., 1965). This syndrome (sleeping sickness) is characterized by progressive lethargy and paresis, unsteady gait, fine muscular tremors affecting hands, face and tongue and slow mental reaction. In cattle, this syndrome has been observed mostly in infections with *T. b. rhodesiense* (Welde et al., 1980), rather than *T. b. brucei*, *T. congolense* or *T. vivax* (Losos and Ikede, 1972; Morrison et al., 1983).

In the studies reported here a high frequency of CNS involvement in cattle with concurrent experimental infections with *T. congolense* and *T. b. brucei* was observed. This is in contrast to the situation in animals infected with either *T. congolense* or *T. b. brucei* alone, indicating an interdependence between the two trypanosome species in the pathogenesis of cerebral trypanosomiasis.

Materials and Methods

Animals

Twelve Boran steers, aged 12–14 months and each weighing approximately 250 kg were obtained from areas known to be free from African trypanosomiasis. They were screened, prior to use, for antibodies to *T. congolense*, *T. b. brucei* and *T. vivax* by immunofluorescence (Wilson, 1969) and enzyme-linked immunosorbent assay (Luckins, 1977) and found to be negative. The mice used were male and female Balb/C, aged 2–3 months and weighing approximately 20 g each.

Parasites

Two trypanosome species were used: *T. congolense* ILNat 3.1, and ILNat 2.1 and *T. b. brucei* MITat 1.2. ILNat 3.1 is a clone derived, in lethally irradiated (900 rads) Balb/C mice, from STIB 212 isolated in Serengeti, Tanzania (Geigy and Kauffmann, 1973). ILNat 2.1 is a clone (Nantulya et al., 1982) derived from an isolate originally collected in 1966 from Southern Kenya (Welde et al., 1974). MITat 1.2 (previously known as clone 221, Doyle et al., 1980), was derived from LUMP 427 isolated in Uganda in 1960 from a sheep (Cunningham and Vickerman, 1962).

The trypanosomes were grown in lethally irradiated (900 rads) mice and separated from infected mouse blood following the method described by Lanham (1968).

Experimental design

Twelve steers were subdivided into 3 groups and inoculated subcutaneously with trypanosomes as follows: *Group 1*: Six animals (B45, B46, B47, B409, B413 and B416) received simultaneous inoculations with 1×10^8 *T. b. brucei* MITat 1.2 and 1×10^7 *T. congolense* ILNat 3.1; *Group 2*: 3 steers (B48, B50 and B51) received 1×10^8 MITat 1.2 a year after infection with 1×10^7 ILNat 2.1; *Group 3* consisted of 3 steers (B417, B418 and B420) infected with 1×10^8 *T. b. brucei* MITat 1.2 alone. The cattle were maintained in insect-proof accommodation.

Daily samples of jugular blood were collected from the infected cattle using heparinized tubes and examined for the presence of trypanosomes using the blood buffy-coat dark ground/phase contrast technique (Murray et al., 1977). Presence of bloodstream trypanosomes was further tested by subinoculation of blood into irradiated mice.

Blood for preparation of serum was obtained from each animal every third day. Serum was separated and stored at -20°C until use. In addition, cerebrospinal fluid (CSF) was drawn from all the cattle every month by lumbosacral puncture under tranquilization or by aspirating through the

atlanto-occipital space at necropsy. The purity of CSF with regard to contamination by blood was checked for by examining Cytospin preparations for red cells. The CSF collected was screened for the presence of trypanosomes by direct examination of wet smear preparations and by subinoculation into lethally-irradiated (900 rads) mice. The infecting trypanosomes as well as those recovered from the CSF during the course of trypanosomiasis were tested for sensitivity to normal human serum using the Blood Incubation Infectivity Test (BIIT) as described by Rickman and Robson (1970). The white cell content of CSF was assessed using a haemocytometer. Following removal of cells by centrifugation, the remaining CSF was stored at -20°C . The serum and CSF samples stored were later tested for antibodies against the infecting trypanosomes by solid-phase radioimmunoassay.

Antisera

Antisera against bovine immunoglobulins were prepared in goats (McGuire et al., 1979) and labelled with ^{125}I iodine (Tsu and Herzenberg, 1980).

Solid-phase radioimmunoassay (S-RIA)

Two variable antigen types (VATs), ILNat 3.1 and MITat 1.2, were used. Trypanosomes were separated from infected mouse blood and washed three times in phosphate-buffered saline glucose (PSG) pH 8.0 (Lanham, 1968) and 1×10^5 trypanosomes dispensed into each well of flexible microtiter plates and fixed with 0.25% glutaraldehyde (Black et al., 1982). This concentration of glutaraldehyde was found to preserve the surface coat of trypanosomes without affecting the antigenicity.

Sera and CSF collected from infected cattle were assayed for antibody activity against glutaraldehyde-fixed trypanosomes as described by Masake et al. (1983). The microtiter plate wells were cut apart with a hot wire, individual wells placed into tubes and bound radioactivity counted in a Packard 5360 scintillation spectrometer.

The specific binding was determined graphically by comparing the dilution at which both the pre- and post-infection CSF or sera titrated down to background (^{125}I and carrier). The points at which the pre- and post-infection CSF or serum line graphs intercepted the background line were determined. The difference between the intercepts gave the actual antibody titre in the post-infection CSF or sera expressed in \log_{10} dilutions.

Necropsy

Eight steers which manifested clinical cerebral trypanosomiasis were killed in extremis between 2.5 and 5 months following *T. b. brucei* infection, while the remaining 4 were slaughtered at the end of the experimental period (9.5 months after *T. b. brucei* infection). At necropsy the brain and spinal cord were carefully dissected out and fixed in large quantities of mercuric chloride-formol solution for one week. Processed tissues were embedded in paraffin wax, sectioned at $6 \mu\text{m}$ thickness and stained with haematoxylin and eosin.

Results

Parasitaemia

Cattle developed a fluctuating parasitaemia of variable duration. Animals which received *T. b. brucei* alone (Group 3) developed relatively low parasitaemic peaks of up to 5×10^3 per ml, with short and frequent remissions for the first 5 weeks, after which the parasites were rarely detected in peripheral blood (Fig. 1). Cattle inoculated with *T. congolense* ILNat 2.1 (Group 2) showed frequent variation in parasite counts up to 5×10^6 per ml during the first 3

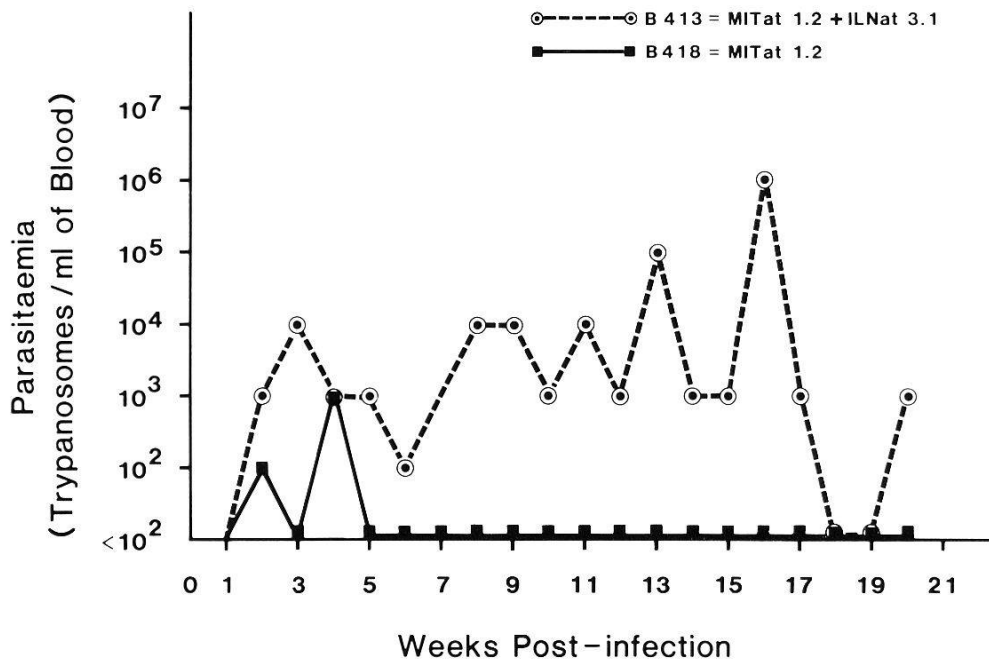


Fig. 1. The levels of parasitaemia in cattle infected simultaneously with *T. b. brucei* and *T. congolense* (○---○) or *T. b. brucei* alone (■—■).

months and thereafter parasites were rarely detectable until the time of superinfection with *T. b. brucei*. After superinfection with *T. b. brucei*, one animal (B48) of Group 2 showed detectable parasitaemia on one occasion only. In contrast, the remaining 2 cattle (B50 and B51) of Group 2 and the six animals exposed to simultaneous mixed infections with *T. b. brucei* and *T. congolense* (Group 1) maintained a parasitaemic plateau with occasional drops throughout the infection (Fig. 1). Cattle killed in extremis had a high parasitaemia of approximately 5×10^5 parasites/ml.

Parasites detected in mixed infection by phase contrast microscopy on buffy coat consisted of both *T. congolense* and *T. b. brucei* during the first 4 weeks of the disease. Later in the infection, however, only *T. congolense* was consistently detected by this technique, while *T. b. brucei* was only revealed by subinoculation of blood into irradiated Balb/C mice.

Clinical course

Three animals in Group 2 developed a mild anaemia after infection with *T. congolense* ILNat 2.1. The PCV dropped from 35% to 28% but rose to pre-infection level by the second month of infection. At the time of superinfection with *T. b. brucei* (twelve months later), their PCV was approximately 35%. Following infection with *T. b. brucei* the 12 animals (Groups 1, 2 and 3) showed a gradual drop of packed cell volume (PCV) from approximately 35% to below 20%. The animals infected with *T. b. brucei* alone slowly regained their PCV levels to near the original state (32%). Such a recovery in PCV was not, however, observed in cattle which received mixed trypanosomal infections.

The six animals in Group 1, which received mixed infections simultaneously, and two of the three (B50 and B51) that were superinfected with *T. b. brucei* one year after infection with *T. congolense* (Group 2) developed signs of cerebral trypanosomiasis. The animals in Group 2 had not shown any signs of CNS involvement during the one year of chronic infection with *T. congolense*. Clinical signs of CNS involvement were detected 3 months after superinfection with *T. b. brucei*. Neurological disturbances consisting of ataxia, depression and occasional circling were observed in the 8 animals. These animals eventually became recumbent. During this stage six of them developed opisthotonus while one steer occasionally paddled the hind feet. The animals were ultimately killed in extremis between 2.5 and 5.0 months post-infection with *T. b. brucei*.

Cattle inoculated with *T. b. brucei* MITat 1.2 alone (B417, B418 and B420) did not show clinical signs of cerebral trypanosomiasis throughout the experimental period of 9.5 months.

Pathological findings

The average white cell count in the pre-infection CSF of the 12 experimental cattle was 1×10^4 cells/ml. The number of cells in the CSF during infection showed little deviation from pre-infection levels regardless of whether the animals had clinical central nervous system disorder.

Cerebrospinal fluid of the experimental cattle was screened on a monthly basis for the presence of trypanosomes. *Trypanosoma b. brucei* was isolated at 3, 5 and 5.5 months from the CSF of 3 animals in Group 1 (B45, B46 and B413) which received *T. b. brucei* and *T. congolense* simultaneously while *T. congolense* was isolated from 1 steer in Group 2 (B51) 2 months following *T. b. brucei* infection. The *T. b. brucei* parasites isolated from the CSF as well as those used for infecting the animals were found to be sensitive to human serum by the BIIT. The presence of trypanosomes in CSF had no correlation with the intensity of clinical symptoms. There were no lesions in the ependyma lining the ventricles of the brain and the central canal of the spinal cord.

At necropsy, gross observations of the brain from the 8 animals with clinical cerebral trypanosomiasis revealed thickened, dull grey meninges and congested meningeal vessels in 6 of them. In one case the sulci contained slightly turbid milky fluid. Histological examination revealed a mild to moderate, disseminated meningoencephalitis in the 6 animals. These lesions were distributed mainly in the frontal lobe, periventricular zone and the brainstem. There were multiple sites of mononuclear cellular infiltrates within the leptomeninges. The degree of the inflammatory response varied from area to area in the same animal. The encephalitis was characterized by a mild to severe lymphocytic-plasmocytic perivascular cuffing, occasionally involving the surrounding parenchyma. Nodular glial aggregates seeded with lymphocytes were disseminated in both the grey and white matter of 2 animals. A very mild lymphocytic infiltration occurred in the choroid plexus of 2 of the animals. Histological study of the

spinal cord revealed a morphologically normal parenchyma and disseminated, mild lymphocytic aggregates within the dura matter.

Specific antibodies to infecting Variable Antigen Types (VATs)

IgM and IgG₁ antibodies to the infecting *T. b. brucei* VAT were not detected in the CSF of cattle infected with *T. b. brucei* alone. However, the CSF from 7

Table 1. Variant-specific IgM antibody activity against *T. b. brucei* MITat 1.2 in cerebrospinal fluid (C) and serum (S) of cattle with mixed MITat 1.2 and *T. congolense* infections

Log ₁₀ antibody titres	Months post infection									
	0		1		2		3		4	
	C	S	C	S	C	S	C	S	C	S
Group 1										
B45	0.0	0.0	2.0	1.5	2.0	2.0	3.0	2.0	2.0	1.0
B46	0.0	0.0	0.0	2.0	0.0	2.0	0.0	2.0	×	×
B47	0.0	0.0	0.0	0.0	2.0	1.0	×	×	–	–
B409	0.0	0.0	1.0	1.0	2.0	2.0	2.0	2.0	1.0	1.5
B413	0.0	0.0	1.0	0.0	2.0	0.0	2.0	1.0	1.0	2.0
B416	0.0	0.0	0.0	0.0	2.0	1.0	1.0	1.0	2.0	0.0
Group 2										
B48	0.0	0.0	0.0	2.0	0.0	1.0	0.0	1.0	0.0	1.0
B50	0.0	0.0	2.0	1.0	2.0	1.0	×	×	–	–
B51	0.0	0.0	0.0	0.0	2.0	1.0	2.0	1.0	×	×

× = animal died

Table 2. Variant-specific IgG₁ antibodies against *T. b. brucei* MITat 1.2 in cerebrospinal fluid (C) and serum (S) of cattle with mixed MITat 1.2 and *T. congolense* infections

Log ₁₀ antibody titres	Months post infection									
	0		1		2		3		4	
	C	S	C	S	C	S	C	S	C	S
Group 1										
B45	0.0	0.0	2.0	2.0	2.0	2.0	2.0	2.0	2.0	2.0
B46	0.0	0.0	0.0	2.0	0.0	2.0	0.0	2.0	×	×
B47	0.0	0.0	0.0	2.0	1.0	2.0	×	×	–	–
B409	0.0	0.0	1.0	1.0	1.0	2.0	2.0	2.0	1.0	2.0
B413	0.0	0.0	0.0	2.0	1.0	2.0	1.0	2.0	1.0	2.0
B416	0.0	0.0	0.0	0.0	1.0	0.0	1.0	0.0	0.0	1.0
Group 2										
B48	0.0	0.0	0.0	2.0	0.0	2.0	0.0	2.0	0.0	2.0
B50	0.0	0.0	2.0	1.0	1.0	1.0	×	×	–	–
B51	0.0	0.0	0.0	1.0	1.0	2.0	2.0	2.0	×	×

× = animal died

Table 3. Variant-specific IgM antibody activity against *T. congolense* ILNat 3.1 in cerebrospinal fluid (C) and serum (S) of cattle infected simultaneously with ILNat 3.1 and *T. b. brucei* MITat 1.2

Log ₁₀ antibody titres	Months post infection									
	0		1		2		3		4	
	C	S	C	S	C	S	C	S	C	S
B45	0.0	0.0	0.0	1.5	0.0	2.5	1.0	3.0	0.0	3.0
B46	0.0	0.0	1.0	3.0	2.0	3.5	2.0	4.0	×	×
B47	0.0	0.0	0.0	1.0	1.0	2.0	×	×	–	–
B409	0.0	0.0	1.0	1.5	1.0	2.0	1.0	1.0	0.0	2.0
B413	0.0	0.0	0.0	1.0	1.5	1.0	1.0	1.0	1.0	1.0
B416	0.0	0.0	0.0	0.0	1.0	1.0	1.0	1.0	1.0	1.0

× = animal died

Table 4. Variant specific IgG₁ antibody activity against *T. congolense* ILNat 3.1 in cerebrospinal fluid (C) and serum (S) of cattle infected simultaneously with ILNat 3.1 and *T. b. brucei* MITat 1.2

Log ₁₀ antibody titres	Months post infection									
	0		1		2		3		4	
	C	S	C	S	C	S	C	S	C	S
B45	0.0	0.0	0.0	1.0	1.0	1.0	1.0	1.0	1.0	1.0
B46	0.0	0.0	1.0	0.0	0.0	0.0	0.0	0.0	×	×
B47	0.0	0.0	0.0	1.0	1.0	1.0	×	×	–	–
B409	0.0	0.0	0.0	0.0	0.0	1.0	0.0	1.0	0.0	1.0
B413	0.0	0.0	0.0	1.0	0.0	1.0	1.0	2.0	1.0	2.0
B416	0.0	0.0	0.0	2.0	1.0	2.0	1.0	2.0	1.0	2.0

× = animal died

out of 9 steers with mixed infections contained antibodies to the infecting *T. b. brucei* VAT. The antibody titres varied from 10 to 1,000 fold and appeared 1–2 months post-infection (Tables 1 and 2). Antibodies to *T. congolense* ILNat 3.1 were also detected in the CSF of animals infected simultaneously with ILNat 3.1 and *T. b. brucei* MITat 1.2 (Tables 3 and 4).

The VAT-specific antibody titres in the CSF did not correlate with those in the serum at all corresponding time points except in the case of IgG-1 antibodies in one animal, B45 (Table 2) and IgM in B416 (Table 3).

Discussion

The studies reported here have demonstrated a higher incidence of cerebral trypanosomiasis in mixed infection with *T. congolense* and *T. b. brucei* as

compared to the animals infected with either *T. congolense* or *T. b. brucei* alone. Variable antigen type-specific antibodies to the original clones were detected in the CSF and serum of the animals manifesting CNS disorder. In most of the animals, however, there was neither temporal nor quantitative correlation between CSF and serum VAT-specific antibodies.

Absence of both clinical and histological evidence of cerebral trypanosomiasis in cattle infected with *T. b. brucei* alone was not surprising since CNS involvement has rarely been observed in cattle infected with *T. b. brucei* alone. Indeed in the literature, only eight cases of bovine cerebral trypanosomiasis have been attributed to *T. b. brucei* (Morrison et al., 1983). In that study, however, 4 of the animals did not show signs of CNS involvement until after treatment with Berenil. Berenil treatment would therefore, seem to predispose *T. b. brucei* infected cattle to CNS involvement. This also appears to be the case in infections with *T. vivax* (Masake, unpublished observations) as well as *T. b. brucei* in mice (Jennings and Gray, 1983). Jennings and Gray (1983) reported that Berenil treatment induced acute meningoencephalitis in mice. The mechanisms by which such treatment would lead to the development of CNS disorder, however, are unclear.

In the present study, the high frequency of CNS involvement in cattle with mixed infections would suggest an interdependence between *T. congolense* and *T. b. brucei* in the pathogenesis of cerebral trypanosomiasis. *Trypanosoma congolense* has a predilection for the walls of the microvasculature (Banks, 1978). Damage to the brain microvasculature by *T. congolense*, either mechanically (Losos and Ikede, 1972) or through elaboration of toxic principles (Tizard and Ringleberg, 1973; Tizard and Homes, 1976) could facilitate entry of *T. b. brucei* into the extravascular space in the brain parenchyma, thereby giving rise to cerebral trypanosomiasis. Although *T. congolense* was isolated from the CSF of one animal, and antibodies to the infecting *T. congolense* VAT were demonstrated in the CSF of animals with mixed infection, it is not certain that *T. congolense* contributed directly to the CNS pathology in these animals.

The lack of direct correlation between CSF and serum antibody titres in most animals would suggest that there was a *de novo* synthesis of antibodies in the CSF indicating either an active infection or presence of circulating surface antigens in the brain parenchyma. This phenomenon of *de novo* synthesis of antibodies found in CSF has been implicated in human trypanosomiasis (Greenwood and Whittle, 1973).

Trypanosoma b. brucei was isolated from the CSF of 3 animals with cerebral trypanosomiasis while *T. congolense* was isolated from the fourth animal. The infecting *T. b. brucei* VAT and the *T. b. brucei* populations from CSF were both human serum sensitive, indicating that they had *T. b. brucei* characteristics. The high frequency of invasion of the central nervous system by trypanosomes in mixed infections may pose serious problems to chemotherapy. This may be so because, firstly, mixed infections are common under field conditions

and secondly, the commonly used anti-trypanosomal compounds do not readily cross the blood-brain barrier (Gutteridge and Coombs, 1977).

Acknowledgments

The authors are grateful to Ms. V. Shitakha, Ms. C. Nkonge, Messrs. F. McOdimba, J. Kamau, D. Bovell, P. Belsoi and J. Maloba for their technical assistance and Ms. M. Kanyugo for typing the manuscript. – This is ILRAD publication number 258.

- Banks K. L.: Binding of *Trypanosoma congolense* to the walls of the small blood vessels. *J. Protozool.* 25, 241–245 (1978).
- Black S. J., Hewett R. S., Sendashonga C. N.: *Trypanosoma brucei* variable surface antigen is released by degenerating parasites but not by actively dividing parasites. *Parasit. Immunol.* 4, 233–244 (1982).
- Cunningham M. P., Vickerman K.: Antigenic analysis of the *Trypanosoma brucei* group using the agglutination reaction. *Trans. roy. Soc. trop. Med. Hyg.* 56, 48–59 (1962).
- Doyle J. J., Hirumi H., Hirumi K., Lupton E. N., Cross G. A. M.: Antigenic variation in clones of animal-infective *Trypanosoma brucei* derived and maintained in vitro. *Parasitology* 80, 359–369 (1980).
- Geigy R., Kauffmann M.: Sleeping sickness survey in the Serengeti Area (Tanzania) 1971. Examination of large mammals for trypanosomes. *Acta trop. (Basel)* 30, 12–23 (1973).
- Greenwood B. M., Whittle H. C.: Cerebrospinal-fluid IgM in patients with sleeping sickness. *Lancet* 1973/II, 525–527.
- Gutteridge W. E., Coombs G. H.: *Biochemistry of parasitic protozoa*, p. 20. MacMillan, London 1977.
- Jennings F. W., Gray G. D.: Relapsed parasitaemia following chemotherapy of chronic *T. brucei* infections in mice and its relation to cerebral trypanosomes. *Contr. Microbiol. Immunol.* 7, 147–154 (1983).
- Lanham S. M.: Separation of trypanosomes from the blood of infected rats and mice by anion exchangers. *Nature (Lond.)* 218, 1273–1274 (1968).
- Losos G. J., Ikede B. O.: Review of pathology of disease in domestic and laboratory animals caused by *Trypanosoma congolense*, *T. vivax*, *T. brucei*, *T. rhodesiense* and *T. gambiense*. *Vet. Pathol.* 9 (suppl.), 1–71 (1972).
- Luckins A. G.: Detection of antibodies in trypanosome infected cattle by means of microplate enzyme-linked immunosorbent assay (ELISA). *Trop. anim. Hlth Prod.* 9, 53–63 (1977).
- Manuelidis E. E., Robertson D. H. H., Amberson J. M., Polak M., Haymaker W.: *Trypanosoma rhodesiense* encephalitis. *Acta neuropathol.* 5, 176–204 (1965).
- Masake R. A., Musoke A. J., Nantulya V. M.: Specific antibody responses to the variable surface glycoproteins of *Trypanosoma congolense* in infected cattle. *Parasit. Immunol.* 5, 345–355 (1983).
- McQuire T. C., Musoke A. J., Kurtti T.: Functional properties of bovine IgG₁ and IgG₂: interaction with complement, macrophages and skin. *Immunology* 38, 249–256 (1979).
- Morrison W. I., Murray M., Whitelaw D. D., Sayer P. D.: Pathology of infection with *Trypanosoma brucei*: disease syndromes in dogs and cattle resulting from severe tissue damage. *Contr. Microbiol. Immunol.* 7, 103–119 (1983).
- Mott F. W.: Histological observations on the changes in the nervous system in trypanosome infections, especially sleeping sickness and dourine, and their relation to syphilitic lesions of the nervous system. *Arch. Neurol. (Lond.)* 3, 581–646 (1907).
- Murray M., Murray P. K., McIntyre W. I. M.: An improved parasitological technique for the diagnosis of African trypanosomiasis. *Trans. roy. Soc. trop. Med. Hyg.* 71, 325–326 (1977).

- Nantulya V. M., Musoke A. J., Rurangirwa F. R., Barbet A. F., Ngaira J. M., Katende J. M.: Immunodepression in African trypanosomiasis: the role of antigenic competition. *Clin. exp. Immunol.* 47, 234–242 (1982).
- Rickman L. R., Robson J.: The testing of proven *Trypanosoma brucei* and *T. rhodesiense* strains by the blood incubation infectivity test. *Bull. Wld Hlth Org.* 42, 911–916 (1970).
- Tizard I. R., Holmes W. L.: The generation of toxic activity from *Trypanosoma congolense*. *Experientia (Basel)* 32, 1533–1534 (1976).
- Tizard I. R., Ringleberg C. P.: Release of biologically active material from dying *Trypanosoma congolense* in rats. *Trans. roy. Soc. trop. Med. Hyg.* 67, 885 (1973).
- Tsu T. T., Herzenberg L. A.: Solid-phase radioimmunoassays. In: *Selected methods in cellular immunology* (ed. by B. B. Mishell and S. M. Shiiigi), p. 373. W. H. Freeman, San Francisco 1980.
- Welde B. T., Lotzsch R., Sadun E. H., Williams J. S., Warui G.: *Trypanosoma congolense*: 1. Clinical observations of experimentally infected cattle. *Exp. Parasit.* 36, 6–19 (1974).
- Welde B. T., Kovatch R. M., Hockmeyer W. T., Owiti S., Masaba S. C., Arap Siongok T.: *Trypanosoma brucei rhodesiense*: experimental infections in cattle. In: *Recent developments in medical research in Eastern Africa* (ed. by A. R. Njogu, P. M. Tukei and J. M. D. Roberts), p. 187–203. Africa Science International Publishing Ltd., Nairobi 1980.
- Wilson A. J.: Value of indirect fluorescent antibody test as a serological aid to diagnosis of *Glossina*-transmitted bovine trypanosomiasis. *Trop. anim. Hlth Prod.* 1, 89–95 (1969).