

Zeitschrift: Schweizer Archiv für Tierheilkunde SAT : die Fachzeitschrift für Tierärztinnen und Tierärzte = Archives Suisses de Médecine Vétérinaire ASMV : la revue professionnelle des vétérinaires

Herausgeber: Gesellschaft Schweizer Tierärztinnen und Tierärzte

Band: 116 (1974)

Heft: 10

Artikel: Ependymoma of the Spinal Cord in a Young Dog

Autor: Teucher, E. / Cherrstrom, E.C.

DOI: <https://doi.org/10.5169/seals-593475>

Nutzungsbedingungen

Die ETH-Bibliothek ist die Anbieterin der digitalisierten Zeitschriften. Sie besitzt keine Urheberrechte an den Zeitschriften und ist nicht verantwortlich für deren Inhalte. Die Rechte liegen in der Regel bei den Herausgebern beziehungsweise den externen Rechteinhabern. [Siehe Rechtliche Hinweise.](#)

Conditions d'utilisation

L'ETH Library est le fournisseur des revues numérisées. Elle ne détient aucun droit d'auteur sur les revues et n'est pas responsable de leur contenu. En règle générale, les droits sont détenus par les éditeurs ou les détenteurs de droits externes. [Voir Informations légales.](#)

Terms of use

The ETH Library is the provider of the digitised journals. It does not own any copyrights to the journals and is not responsible for their content. The rights usually lie with the publishers or the external rights holders. [See Legal notice.](#)

Download PDF: 16.03.2025

ETH-Bibliothek Zürich, E-Periodica, <https://www.e-periodica.ch>

Schweiz. Arch. Tierheilk. 116, 461-466, 1974

Department of Veterinary Biology (Pathology) and Department of Clinical Sciences,
School of Veterinary Medicine, University of Minnesota, St. Paul, Minnesota

Ependymoma of the Spinal Cord in a Young Dog

E. Teuscher¹ and E. C. Cherrstrom

Neoplasms of the spinal cord in dogs have not been frequently reported. Concerning the general occurrence of neoplasms (including ependymomas) of the central nervous system and spinal cord, reviews have been made by Innes and Saunders (1962), Moulton (1962), Schiefer and Dahme (1962), Luginbühl (1962 and 1963), Luginbühl, Fankhauser and McGrath (1968) and Jubb and Kennedy (1970). An ependymoma of the spinal cord has been reported by Hayes and Schiefer (1969) in a 12-year old spayed female Boston terrier. Schiefer and Dahme (1962) described a neoplastic lesion in a 2-year old male Boxer, which was similar to an ependymoma, epithelial type, but because of histological details, they decided that the most probable diagnosis was hamartoma.

In the brain a special form of ependymoma is the choroid plexus papilloma as described by Kurtz and Hanlon (1971) and Jakob (1959). Savage, Isa and Fischer (1962) described a malignant ependymoma in a dog, but no rosettes or blepharoblasts were seen. The localization at the border of the fourth ventricle and an epithelial, carcinoma-like structure (according to the photograph) suggested this diagnosis. An ependymoma of the brain has also been described in the cat by Fox et al. (1973).

The present case is considered interesting for three reasons:

1. It is rare (perhaps the first description of this type of spinal cord tumor in the dog).
2. It was found in a very young dog.
3. It was a cause of posterior paralysis in a young dog, indicating that even in a young animal tumors should be considered in a differential diagnosis.

Materials and Methods

A young male Labrador dog, 5½ month old, was euthanatized at the clinic of the College of Veterinary Medicine, University of Minnesota, St. Paul. The records indicated onset of rear limb paresis and paralysis over a period of 2-3 days, six weeks before. No history of trauma or any inciting factor was given. The dog was hospitalized for 3 weeks with no significant improvement and a gradual degeneration. Forelimbs are showing signs of involvement. Radiographs were negative for disc or vertebral lesions. The autopsy was made immediately

¹ Address: Dr. E. Teuscher, UNDP/FAO Office, P.O. Box 322, Denpasar, Bali (Indonesia).

after death. The organs were fixed in formalin, embedded in paraffin and stained with hematoxylin eosin, Goldner's Method, Azan, PAS, Silver impregnation, Masson trichrome staining method and Holzer's glia stain.

Results

Gross lesions

Grossly no lesion was found except in the spinal cord. The brain was normal in appearance. On the dorsal part of the lumbar spinal cord there is a neoplastic mass measuring 2.2 x 1.2 x 0.9 cm (Fig. 1). The neoplasm is light brown and located between L₁ and L₂. It is situated obliquely on the right lateral surface, dorsal from the spinal cord and attached cranially and caudally to the leptomeninges. There is no connection with the dura mater, the growth being below the pachymeninx. The compression of the spinal cord is at its maximum in the central part of the neoplasm. Less than half of the grey matter is visible and the central canal cannot be seen. At this place it gives the impression of being an intramedullary growth. In the cranial part of the tumor, the sulcus ventralis is still present and the central canal can be seen too. The compression is progressively decreasing toward the caudal part of the lesion.

Microscopic findings

The neoplasm is very polymorphic; however in many places, there are epithelial formations, the most characteristic being rosettes and canals similar to normal ependymal structures lining the central canal of the spinal cord (Fig. 2 and 3).

Often the epithelial structures are different and resemble papillary formations. In this case, the epithelial cells are located around a central mass of fibers or cells and surrounded by a clear space (Fig. 4). Many such structures show some analogy with plexus structures, the epithelium being situated around a small vessel.

Both types of structures remind one of the tendencies of ependymal growth in normal animals. Some variations of the epithelial pattern are shown in Figures 6 and 7.

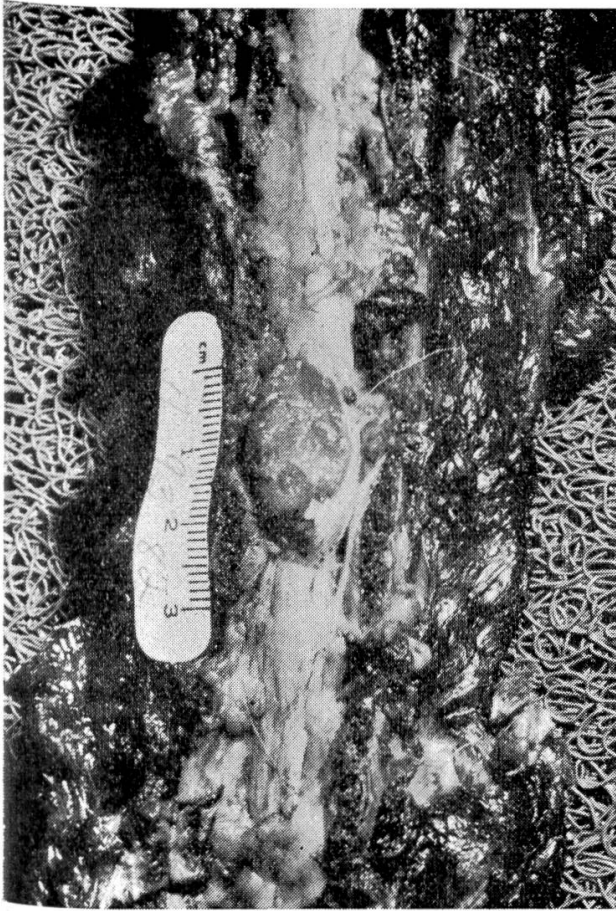
Between the typical epithelial formations connective fibers are sometimes present but scarce. They are numerous around blood vessels but divide the neoplasm in lobules only in parts of the slide. In large areas the cells are undifferentiated and resemble a solid carcinoma and sometimes even a sarcoma (Fig. 5 and 8), but except for the stroma, the cells give the impression of epithelial origin.

Fig. 1 Ependymoma between L₁ and L₂ (gross lesion).

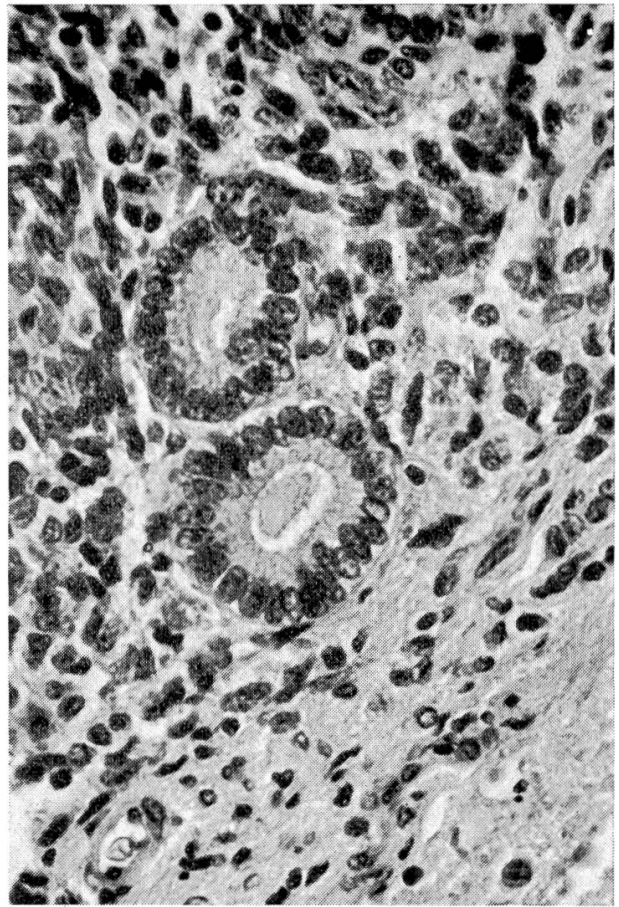
Fig. 2 Typical rosette formation. At the bottom right, a small part of spinal cord tissue is visible. In the larger tubule the dark dots at the margin of the cells are probably blepharoblasts.

Fig. 3 The tubules are less regular and separated by several types of cells.

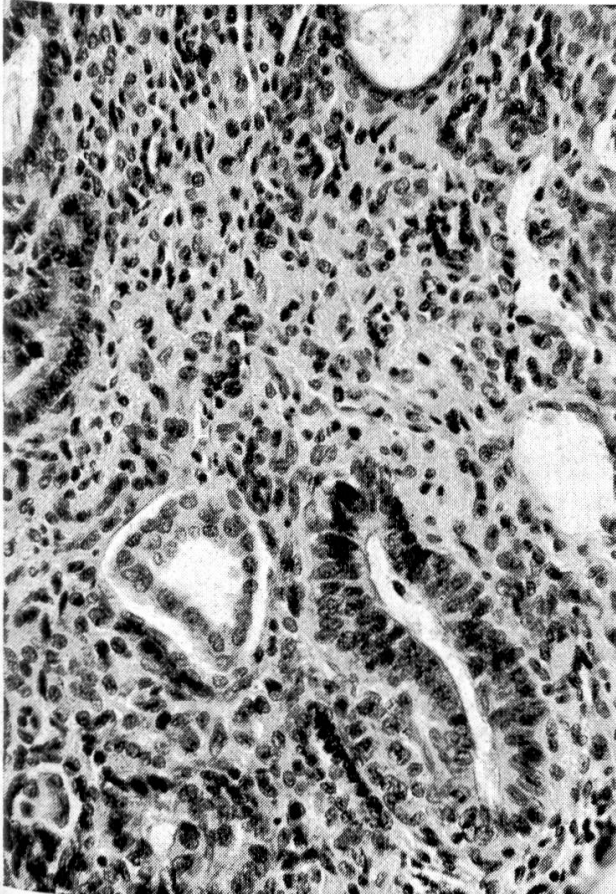
Fig. 4 In the center, the structure is similar to a papillary formation or perhaps a pseudorosette.



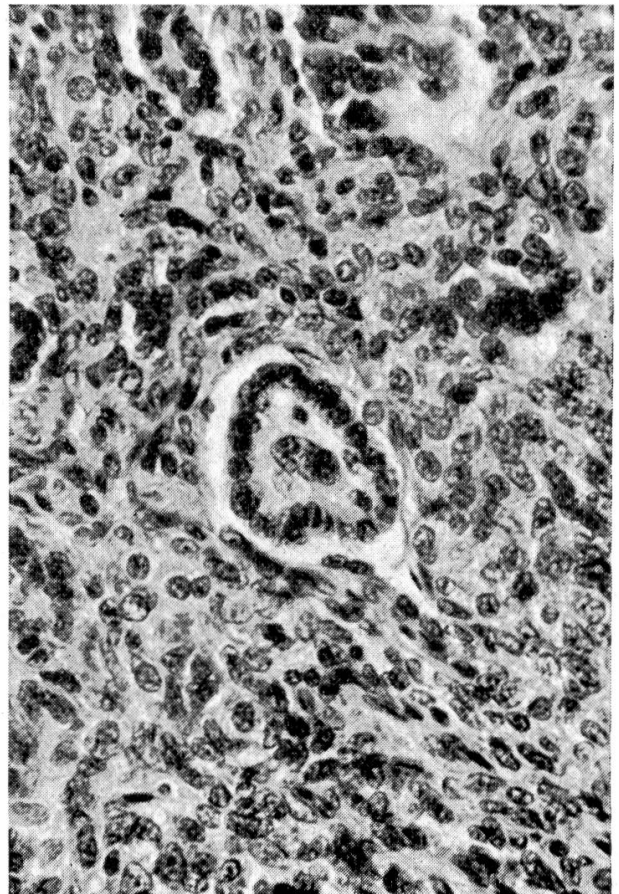
1



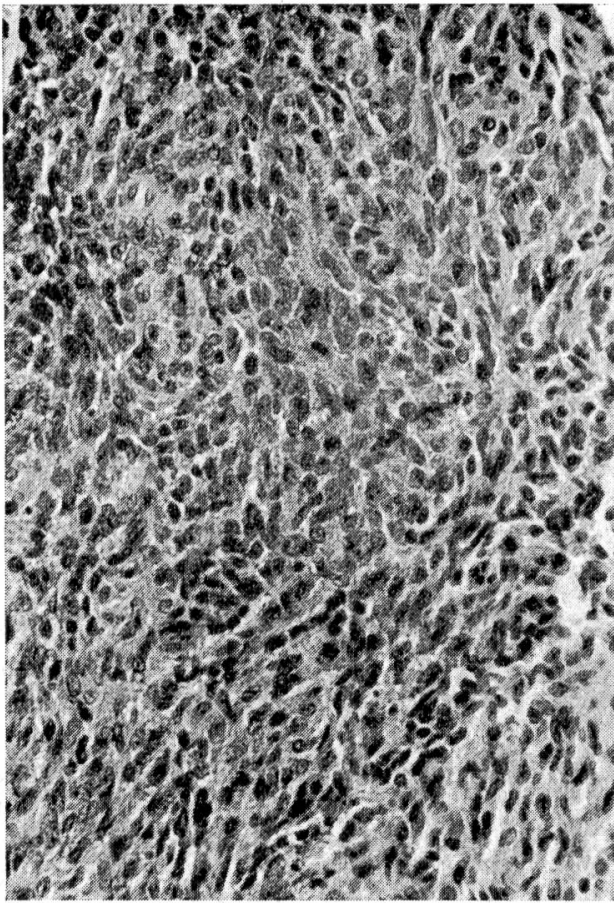
2



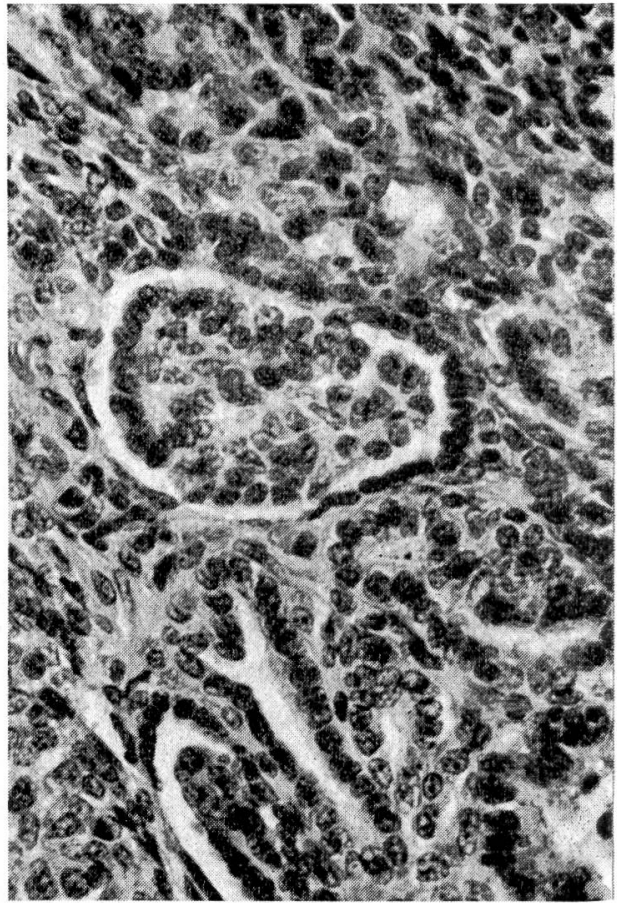
3



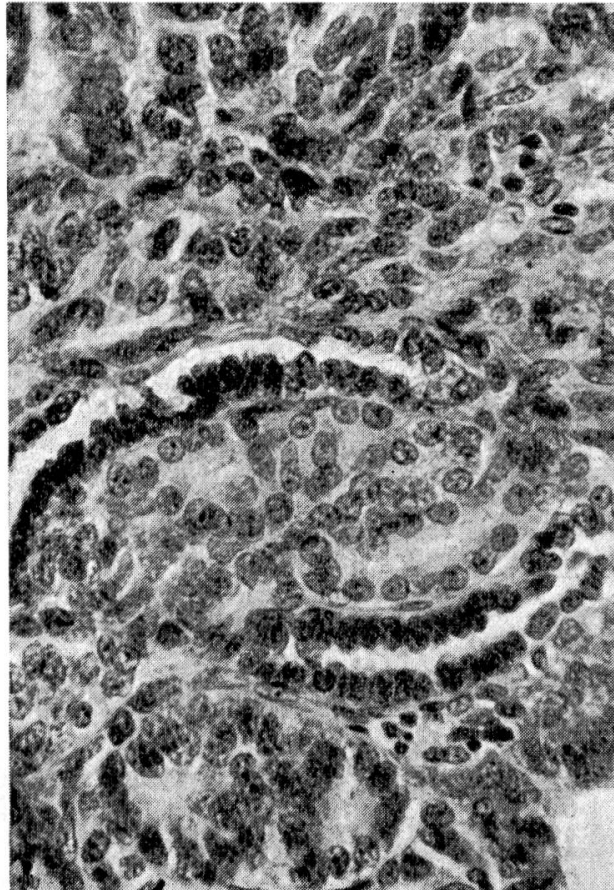
4



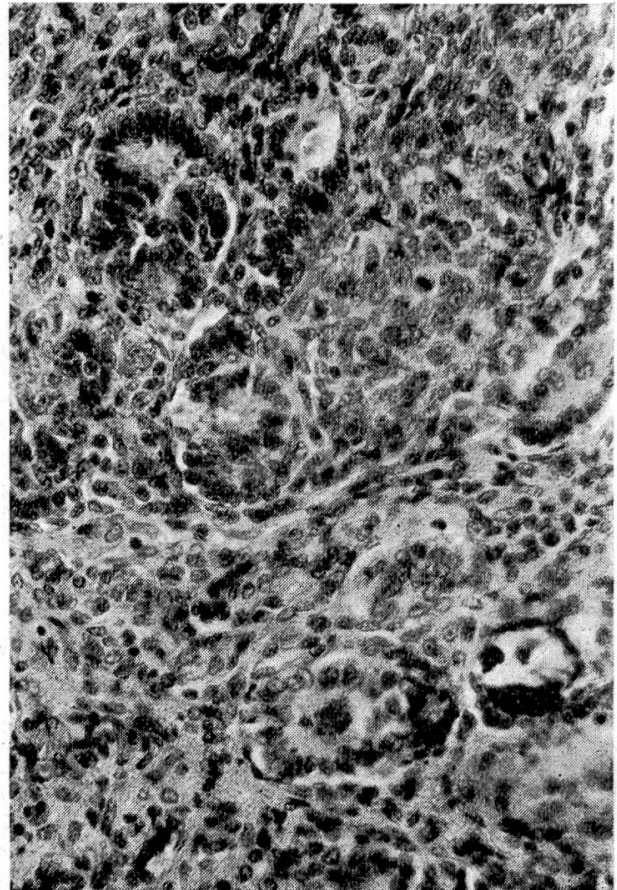
5



6



7



8

Mitotic figures are frequent in some parts of the neoplasm (Fig. 5). Small foci of calcification are present but not numerous (Fig. 8). A few small necrotic areas with secondary inflammation can be seen. In the central part, the neoplasm destroyed half the grey matter (central canal is no more present). In some places the neoplasm has invaded portions of nerve roots.

Cranial from the tumor, there is a dilatation of the central canal of the spinal cord and the ependymal cells are flattened. Distortion and lateral flattening of the spinal cord is present at the level of the lesion, together with a variable degree of white matter degeneration. A few small cavitations and a few hemorrhages are limited to the most affected areas.

In the cervical part the dilatation of the central canal is still visible but less marked.

Although fibers are often present between the rosettes and the epithelial structures (Azan stain), PAS and reticulin stain failed to show any typical basal membranes. No secretion is visible within the epithelial cells with PAS stain.

Discussion

The neoplasm is considered to be an ependymoma, epithelial type. It is a rapidly growing neoplasm, and the destruction of half the grey matter in the most affected parts indicates an intramedullary growth. The histological appearance would correspond to a grade 3 epithelial ependymoma according to the classification of Kernohan (1971). An ependymoma with quite the same structure as in our case is shown in human pathology in Fig. 481 and 482 in the book of Evans (1968). This would be the first malignant ependymoma, epithelial type, described in the spinal cord in a young dog. The case of Savage and Fischer (1962) in the brain is similar, but would be more undifferentiated than the present observation.

Summary

The occurrence of a rare neoplasm of the spinal cord (ependymoma, epithelial type, grade 3 Kernohan) is described in a young dog. This type of tumor is exceptional in domestic animals.

Zusammenfassung

Ein seltener Tumor des Rückenmarks bei einem jungen Hund (Ependymom epithelialen Typs, Grad 3 nach der Klassifikation von Kernohan) wird beschrieben. Diese Tumortypart ist sehr ungewöhnlich bei Haustieren.

Acknowledgements: The authors thank Dr. R. Fankhauser, Bern, Switzerland, for the discussion of the slides, and Dr. H. J. Kurtz, St. Paul, Minnesota, U. S. A., for a review of the text.

Fig. 5 Here, the aspect of the neoplasm reminds one of a compact carcinoma or sarcoma. Mitotic figures are frequent.

Fig. 6 and 7 The microphotographs show the variability of the tubular structures.

Fig. 8 Small foci of calcification (top left) and polymorphic structure of the neoplasm.

Résumé

Une tumeur de la moelle épinière chez un jeune chien est décrite. Il s'agit d'un épendymome du type épithélial (grade 3 selon la classification de Kernohan), néoplasme exceptionnellement rare chez les animaux domestiques.

Riassunto

Un tumore del midollo spinale in un giovane cane viene descritto. Si tratta di un ependimoma tipo epiteliale, (grado 3 secondo la classificazione del Kernohan), e anzi di una neoplasia eccezionalmente rara negli animali domestici.

References

Evans R. W.: Histological appearance of tumors (The Williams and Wilkins Company, Baltimore, second edition, 1968). – Fankhauser R. and Luginbühl R.: Zentrales Nervensystem, in Joest, Handbuch der speziellen Pathologischen Anatomie der Haustiere, 3. Auflage, Band III (Paul Parey, Berlin 1968). – Fox J. G., Snyder S. B., Reed C. and Campbell L. H.: Malignant ependymoma in a cat. *J. Small Anim. Pract.* 14, 23–26 (1973). – Hayes K. C. and Schiefer B.: Primary tumors in the CNS of Carnivores. *Path. Vet.* 6, 94–116 (1969). – Innes J. R. M. and Saudners L. Z.: Comparative Neuropathology (Academic Press, New York 1962). – Jakob K.: Beitrag zum Plexuspapillom. *Berl.-Münch. tierärztl. Wschr.* 76, 390 bis 393 (1963). – Jubb K. and Kennedy P.: Pathology of domestic animals, Vol. 2 (Academic Press, New York, second edition, 1970). – Kernohan J. W., in Pathology of the Nervous System, Minkler J., editor, Vol. 2 (McGraw-Hill Book Company, New York 1971). – Kurtz H. J. and Hanlon G. F.: Choroid plexus papilloma in a dog. *Path. Vet.* 8, 91–95 (1971). – Luginbühl H.: Zur vergleichenden Pathologie der Tumoren des Nervensystems, I. Teil. *Schw. Arch. Tierheilk.* 104, 305–322 (1962). – Luginbühl H.: Comparative aspects of tumors of the nervous system. *Ann. N. Y. Acad. Sci.* 108, 702–721 (1963). – Luginbühl H., Fankhauser R. and McGrath J. T.: Spontaneous Neoplasms of the Nervous System in Animals. Progress in Neurological Surgery, Vol. 2, 85–164 (S. Karger, Basel-New York 1968). – McGrath J. T.: Neurologic examination of the dog with clinicopathologic observations (Lea and Febiger, Philadelphia 1960). – Moulton J. E.: Tumors in domestic animals (University of California Press, Berkeley 1961). – Savage A., Isa J. M. and Fischer W.: Malignant ependymoma in a dog. *Cornell Vet.* 52, 68–70 (1962). – Schiefer B. and Dahme E.: Primäre Geschwülste des ZNS bei Tieren. *Acta Neuropathologica* 2, 202–212 (1962). – Sloof J., Kernohan J. W. and Maccarty C. S.: Primary intermedullary tumors of the spinal cord and filum terminale. (W. B. Saunders Company, Philadelphia, London 1964.)

BUCHBESPRECHUNG

Deutsches Gesundheitsrecht. Von Dr. E. Etmer und R. S. Schulz, München 25 und Percha am Starnberger See. 8., 9. und 10. Ergänzungslieferungen 1974. DM 75,- einschließlich Ergänzungen. Stand: 1. April 1974.

Die 8., 9. und 10. Ergänzungslieferung zu dieser umfassenden Vorschriftensammlung ist kürzlich erschienen. Sie enthält u. a. einige Änderungen zu bestehenden Vorschriften und neuerlassene Vorschriften, wie das Gesetz über die Errichtung eines Bundesamtes für Sera- und Impfstoffe, die Verordnungen über Sera- und Impfstoffe nach Art. 17c des Viehseuchengesetzes, Approbations-Ordnung für Apotheker, Kommentar zu den einzelnen Artikeln der Röntgen-Verordnung, Fleischbeschau-Gesetz, Geflügel-Hygiene-Gesetz. Die Sammlung wird somit auf den neuesten Stand gebracht.

Ch. Dapples, Lausanne