

Zeitschrift: Schweizer Archiv für Tierheilkunde SAT : die Fachzeitschrift für Tierärztinnen und Tierärzte = Archives Suisses de Médecine Vétérinaire ASMV : la revue professionnelle des vétérinaires

Herausgeber: Gesellschaft Schweizer Tierärztinnen und Tierärzte

Band: 118 (1976)

Heft: 9

Artikel: Ultrastructural investigations concerning a sporadically occurring meningo-encephalomyelitis of cattle in Switzerland

Autor: Bestetti, G. / Fatzer, R. / Fankhauser, R.

DOI: <https://doi.org/10.5169/seals-592676>

Nutzungsbedingungen

Die ETH-Bibliothek ist die Anbieterin der digitalisierten Zeitschriften. Sie besitzt keine Urheberrechte an den Zeitschriften und ist nicht verantwortlich für deren Inhalte. Die Rechte liegen in der Regel bei den Herausgebern beziehungsweise den externen Rechteinhabern. [Siehe Rechtliche Hinweise.](#)

Conditions d'utilisation

L'ETH Library est le fournisseur des revues numérisées. Elle ne détient aucun droit d'auteur sur les revues et n'est pas responsable de leur contenu. En règle générale, les droits sont détenus par les éditeurs ou les détenteurs de droits externes. [Voir Informations légales.](#)

Terms of use

The ETH Library is the provider of the digitised journals. It does not own any copyrights to the journals and is not responsible for their content. The rights usually lie with the publishers or the external rights holders. [See Legal notice.](#)

Download PDF: 16.03.2025

ETH-Bibliothek Zürich, E-Periodica, <https://www.e-periodica.ch>

Schweiz. Arch. Tierheilk. 118, 351-357, 1976

Institute for comparative Neurology (Prof. R. Fankhauser), University of Bern
and Institute of veterinary Pathology (Prof. F. Guarda), University of Torino

Ultrastructural investigations concerning a sporadically occurring meningo-encephalomyelitis of cattle in Switzerland¹

by G. Bestetti, R. Fatzer and R. Fankhauser²

I. Introduction

Fifteen years ago, Fankhauser (1961 a, b) described a sporadically occurring meningo-encephalomyelitis in Swiss cattle. He emphasized the fact that clinical signs and pathological anatomy were different from the chlamydial "Sporadic bovine encephalomyelitis" known to occur in several parts of the world. Individual cases had been observed during the preceding 3 decades (Frauchiger and Hofmann, 1941), but the disease was recognized with increasing frequency in the fifties. When rabies began to spread in north-eastern Switzerland (from March 1967 onwards), the brains of domestic animals were sent in for rabies examination in fairly large numbers from the endemic areas. A systematic histological control of this material over the past years has corroborated the impression that non-bacterial, non-rabid encephalomyelitides are prevalent among neurological diseases of cattle in this country (Fatzer, 1970; Fatzer and Steck, 1974). A total of over 120 cases have been observed over the years. Details of epizootology, clinical course and histopathological findings have been reported by Fankhauser (1961 a, b) and were confirmed by Billing (1974). Cattle between 1 and 4 years are mainly affected, although cases in animals up to 6 years were recorded. Young calves seem to be spared, an important distinguishing feature from IBR-infections (Bagdadi and Martin, 1974; Lomba et al., 1974). The absence of clinical signs of respiratory tract involvement, the marked difference of average age of the affected animals and the complete absence of serofibrinous inflammation of the serous membranes differentiate the disease from "Sporadic bovine encephalomyelitis" attributed to chlamydial infections.

¹ Supported by grant no. 3.459.75 of the Swiss National Foundation for Scientific Research.

² Address: P.O. Box 2735, CH-3001 Bern, Switzerland.

This entity has first been reported in North America (see Jubb and Kennedy, 1970; Harshfield, 1970), and has since been observed in Japan (Omori et al., 1953, 1954; Ishitani et al., 1954), Czechoslovakia (Konrád and Boháč, 1959; Polony et al., 1961), South Africa (Tustin et al., 1961), Australia (Johnston et al., 1962; McGavin, 1962), Hungary (Csontos and Széky, 1964) and Israel (Kalmar et al., 1967). For additional bibliography, see Harshfield (1970) and Billing (1974).

Both its clinical and anatomo-pathological characteristics permit to differentiate the disease from malignant catarrhal fever.

Fankhauser (1961, a) thought that the meningo-encephalomyelitides of Swiss cattle might be caused by one or several viral agents, and he speculated on a rather widely disseminated, but only occasionally encephalitogenic virus. However, all attempts to isolate such an agent have failed so far (personal communications F. Bürki, Vienna; F. Steck, A. Wandeler, Bern). Therefore, it was considered useful to examine brain material of bovine encephalitis cases electron-microscopically. The present paper reports on preliminary results.

II. Material and Methods

The brains of seven Swiss cattle, negative for rabies and showing the histopathological lesions of the sporadically occurring meningo-encephalomyelitis described by Fankhauser (1961) were examined ultrastructurally. Two histologically negative bovine brains served as controls (see Table 1). Six of the brains had been fixed routinely in neutral formalin 1:9. After histopathological diagnosis, blocks of these brains were put in 1.5% glutaraldehyde buffered with S-Collidin.

In one case, thin slices of fresh brain tissue (1–3 mm) were fixed by immersion in Carnovsky's fluid (2% paraformaldehyde + 2.5% glutaraldehyde in potassium-phosphate buffer) immediately after euthanasia for 12 hours and stored in S-collidin buffer.

The material was post-fixed in an OsO_4 1% solution for 1 hour and embedded in Epon 312. Ultrathin sections were cut with an OMU_2 (Reichert) ultramicrotome and stained for contrast with uranylacetate and lead citrate. The sections were examined with a Philips 300 electron microscope.

III. Electron-microscopic observations

The structures to be described here were observed in the 6 animals whose brains had been fixed in formalin. They were only found within the inflammatory foci. They were almost always located within the cytoplasm, partic-

1) Microorganisms (\uparrow) in the endothelial cytoplasm (E)

L: vascular lumen

ER: erythrocyte (25700 \times)

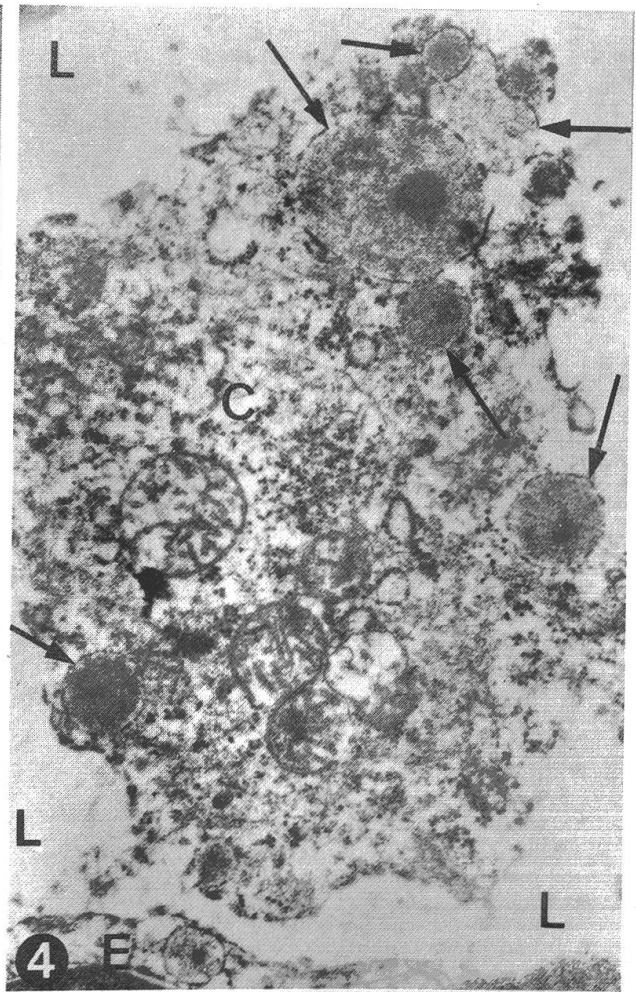
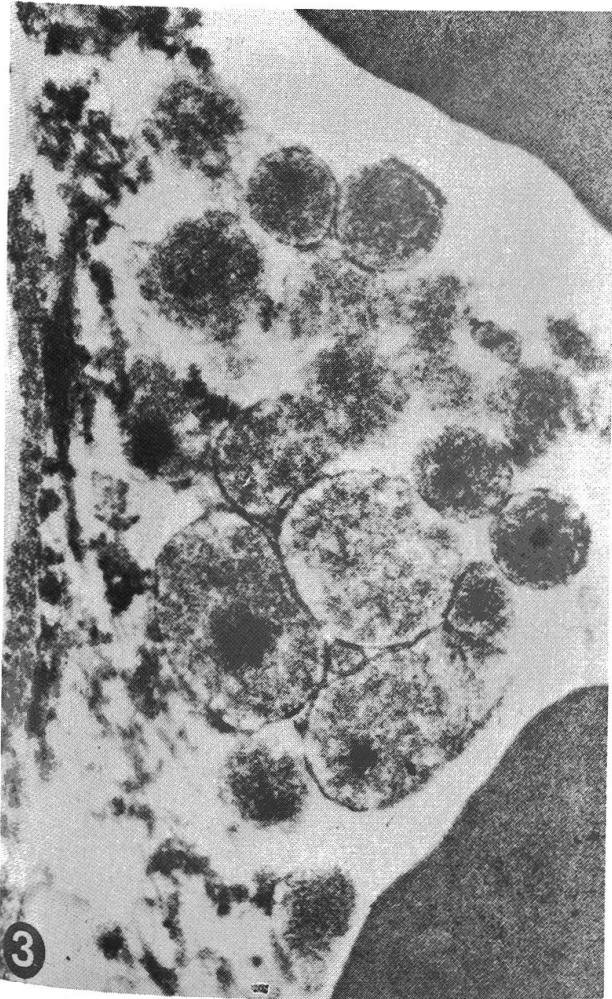
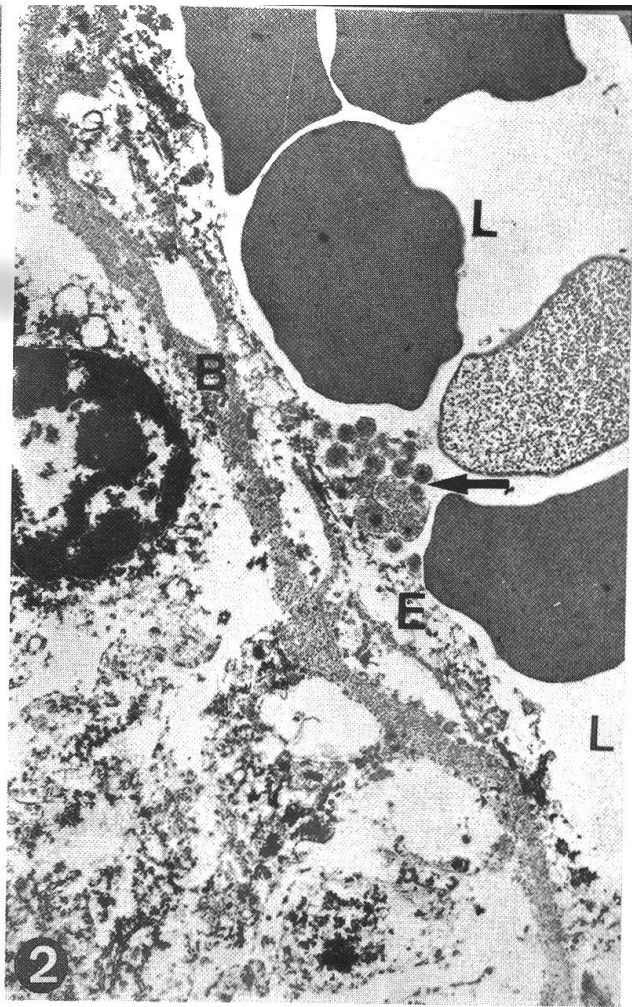
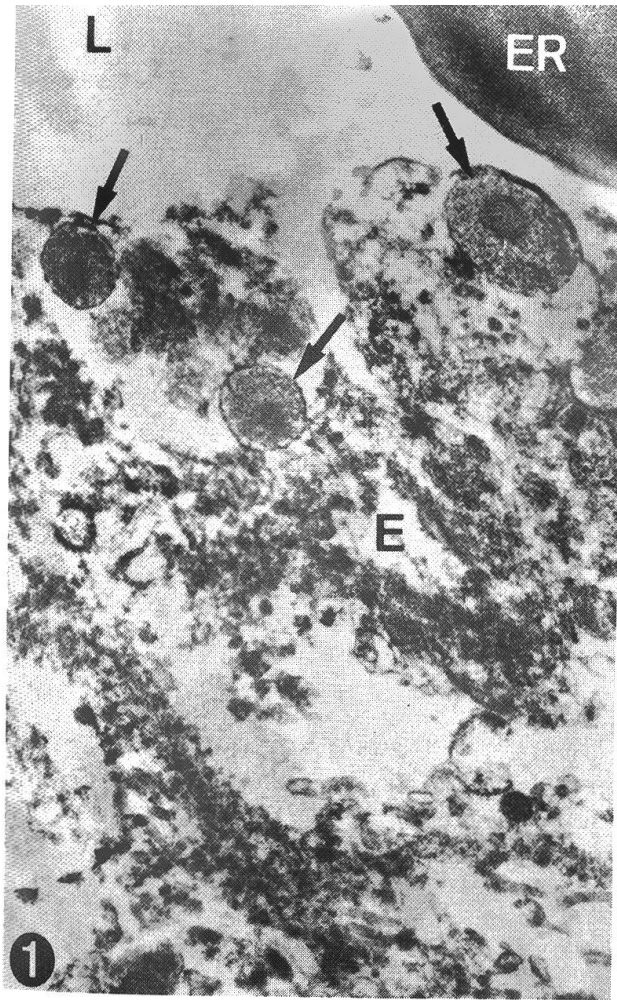
2) Group of microorganisms (\uparrow) in connection with the endothelium (E)

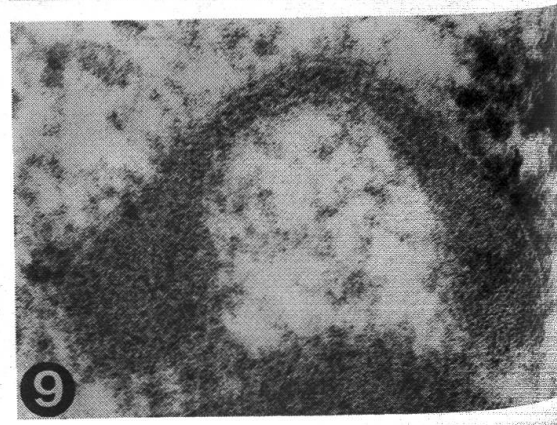
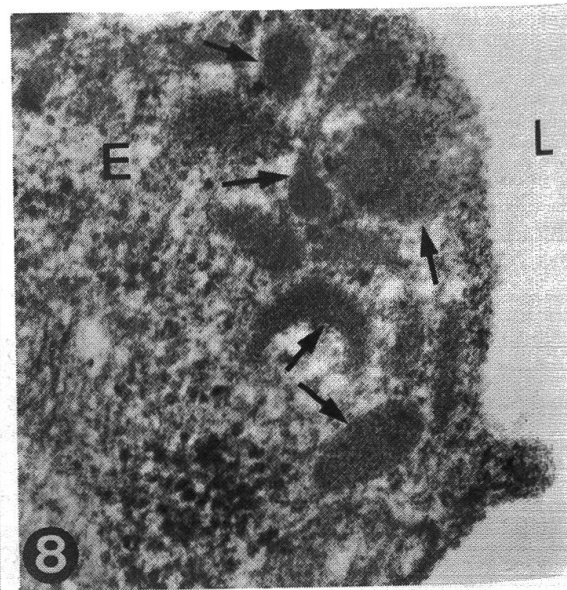
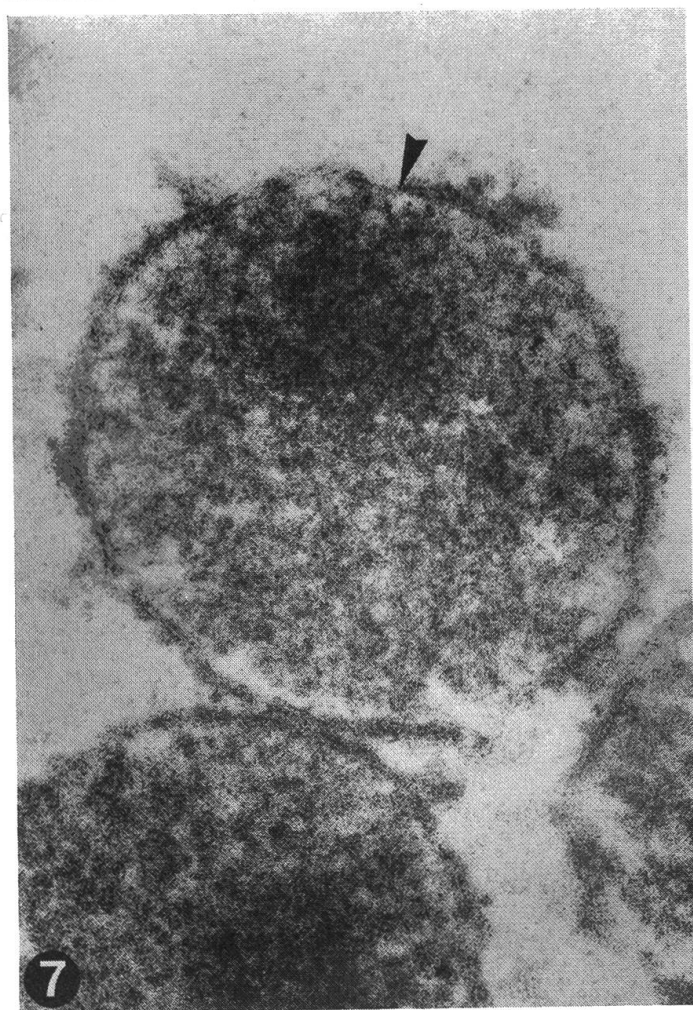
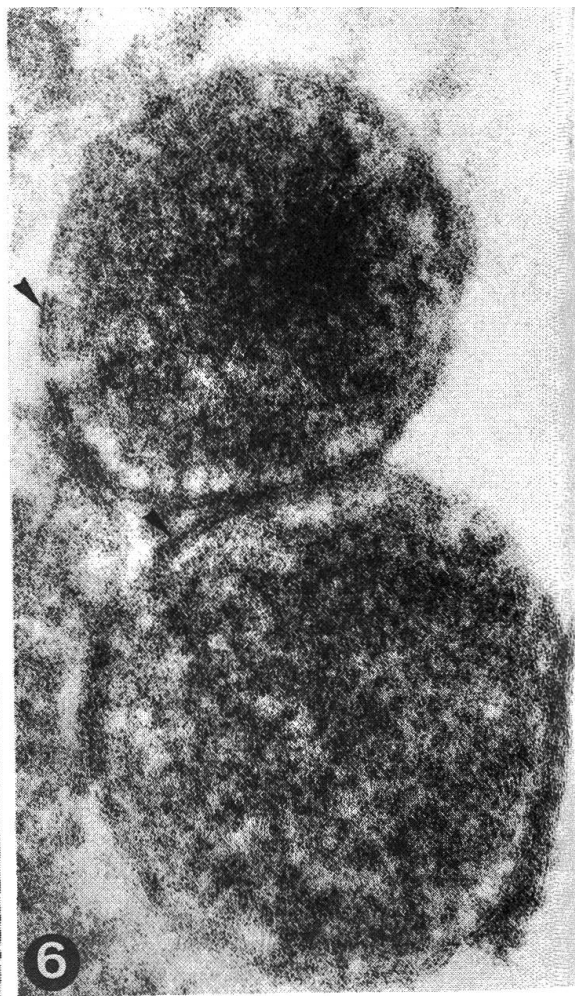
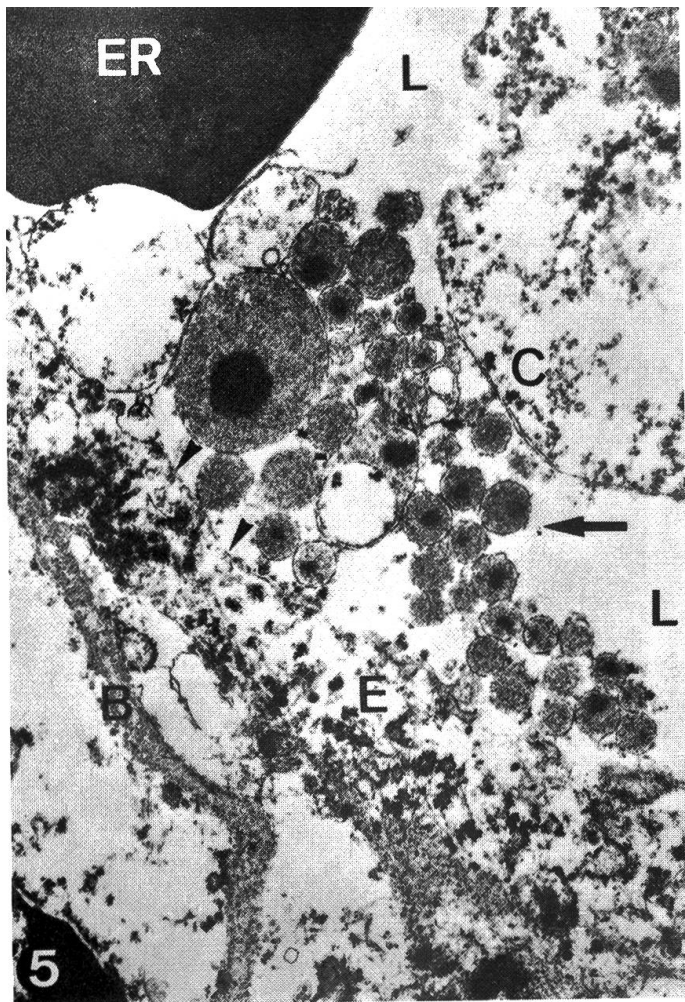
L: vascular lumen

B: basal membrane of the endothelium (8000 \times)

3) Closer view of fig. 2. It can not be decided if the structures are intra- or extra-cellular (34500 \times)

4) Microorganisms (\uparrow) in the cytoplasm of a cell (C) within the vascular lumen (L) close to an endothelial cell (E) (21000 \times)





ularly of endothelial cells (fig. 1), and less frequently in white blood cells within the lumina of vessels (fig. 4) and in infiltrating cells of the vascular cuffs. They were never found in an intranuclear position.

The observed bodies are round, elliptic or irregular, with a maximum diameter or length between 0,3 and 1 mikron (fig. 1-7). They are often densely aggregated in groups of 10 to 20 units (fig. 2, 3, 5), are surrounded by a unit membrane and contain granular material of the size of ribosomes (fig. 6). The area close to the membrane is usually less electron dense than the rest (fig. 6). In the centre, there is often an electron dense area of a maximum diameter of 0.4 mikron (fig. 1-5). Such dense areas can also be located in an eccentric position (fig. 6) or adhering to the internal lamella of the unit membrane (fig. 7).

In the material fixed in Carnowsky's fluid, the structures described above were found rather seldom and then always in a clearly intracellular location. In this case, however, another type of bodies was observed very frequently, and again always with an intracytoplasmic location. These bodies were round, ovoidal or elongated (fig. 8), with two globoid ends about 0.15 mikron in diameter, and connected by a tiny bridge about 350 Å wide (fig. 9). These structures are surrounded by a unit membrane and are electron dense to a degree that no details of their texture can be distinguished (fig. 8, 9).

In the 2 control brains, the structures described here were not observed.

IV. Discussion

First we wish to point out that the preservation of the formalin fixed material was good enough to permit an electron-microscopic evaluation. The critical areas were scrutinized on serial ultrathin sections and rigid criteria were applied to the morphological interpretation of the structures observed. There is no question of describing *mycoplasma-like* structures as is sometimes done in the literature (Dvořák, 1974).

The morphological characteristics, the frequent arrangement in dense aggregations, and the localisation of the structures described, seem to allow a distinction from phagosomes, lysosomes and microbodies. These features and

5) Group of microorganisms (↑) apparently free in the vascular lumen (L)

ER: erythrocyte

C: white blood cell

E: endothelium

(▲): cell membrane of the endothelium

B: basal membrane of the endothelium (15000×)

6) A unit membrane (▲) surrounds the microorganisms. In one of them there is an eccentric, electron dense area. The cytoplasm contains granular material and there is a peripheral electron light zone (130000×)

7) Electron dense area close (▲) to the internal layer of the unit membrane (130000×)

8) Many electron dense and polymorph structures (↑) in a small zone of endothelial cytoplasm (E)

L: vascular lumen (53000×)

9) Electron dense body with two globoid ends connected by a tiny bridge, surrounded by a unit membrane (96000×)

Table 1

	Sex	Age	Histopathology	Fixation	Buffer	Embedding
11577	*	3y	polio-encephalitis and cerebellar meningitis	dec/6/75: neutral form. jan/26/76: glutaraldehyde	S-collidin	Epon
11646	*	1½y	meningo-encephalitis	jan/3/76: neutral form. march/3/76: glutaraldehyde	S-collidin	Epon
11648	*	*	encephalitis (mesencephalon and medulla)	jan/6/76: neutral form. march/3/76: glutaraldehyde	S-collidin	Epon
11697	♀	2½y	polio-encephalitis and meningitis	jan/29/76: neutral form. march/4/76: glutaraldehyde	S-collidin	Epon
11729	*	2½y	polio-encephalitis and meningitis	feb/3/76: neutral form. march/23/76: glutaraldehyde	S-collidin	Epon
11740	♀	old	disseminated encephalitis	feb/2/76: neutral form. march/3/76: glutaraldehyde	S-collidin	Epon
11919	♀	3y	negative	ap/21/76: n. form. ap/21/76: Carnowsky	may/5/76: glut.	S-collidin Epon
11930	♀	2y	meningo-encephalitis	may/15/76: n. form. may/15/76: Carnowsky	jun/7/76: glut.	S-collidin Epon
12027	♀	4m	negative	jun/4/76: n. form. jun/4/76: Carnowsky	jun/19/76: glut.	S-collidin Epon

* Material for rabies is often submitted without appropriate data

the small size distinguish them from bacteria. On the other hand, their pleomorphism, their size, the presence of granular material and of a rudimentary nucleus without a membrane are all characteristics of microorganisms of a non-viral type (Anderson, 1969). Therefore, three groups of agents are to be considered: Rickettsiae, Chlamydia and Mycoplasmas.

A critical evaluation of the electron-microscopic findings permits the following statements:

1) The observed microorganisms are mainly intracellular, a feature recognized for Mycoplasmas (Anderson, 1969) as well as for Rickettsiae and Chlamydia (Anderson et al., 1965), although most investigators observed Mycoplasmas in an extracellular location.

In fact, some of our microorganisms seem to be located extracellularly, be it free in the vascular lumen (fig. 5) or adhering to the surface of the apical membrane of endothelial cells. However, the cell membrane especially of endothelial cells is known to be readily damaged by formalin fixation, and therefore this statement has to be taken with caution.

2) The size of the observed bodies corresponds better with the one indicated for Mycoplasmas, both Rickettsiae and Chlamydia being conspicuously larger, especially in their mature forms (Anderson et al., 1965).

3) The electron dense structures seen in the case fixed with Carnowsky's fluid have been found in the L-phase of certain Mycoplasmas (Baskerville et al., 1972; Maniloff and Morowitz, 1972), but have not been described for Rickettsiae and Chlamydia. Similar structures were observed in the cytoplasm of epithelial cells in the mammary gland of cows infected experimentally with *Mycoplasma bovis* (Jasper et al., 1969).

4) We never observed a cell wall (not to be confused with the "unit membrane" surrounding our microorganisms), which is in accordance with the descriptions for Mycoplasmas. Both Rickettsiae and Chlamydia regularly have such a structure (Anderson, 1969).

5) An electron dense centre has been described for Chlamydia (Anderson et al., 1965) and Mycoplasmas (Anderson, 1969; Jasper et al., 1969; Maniloff and Morowitz, 1972), but only in Mycoplasmas this "nucleus" seems to be eccentric (Anderson, 1969; Jasper et al., 1969).

In conclusion, the elements observed in our material may be classified as non-bacterial and non-viral microorganisms, similar to Mycoplasmas. It must be stressed that with one exception (*Mycoplasma neurolyticum* of mice: Tully, 1969), there have been no reports on encephalopathies in animals due to Mycoplasmas.

Utmost care is indicated in postulating a causal relationship between the morphological finding of an "agent" in the tissues, and the histopathological substratum of a clinical disease: In our case between the observed organisms and the sporadically occurring, non-purulent meningo-encephalomyelitis of cattle (Fankhauser, 1961) in Switzerland and southern Germany (Billing, 1974). The constant association of the organisms with the

histological lesions in all cases examined electron-microscopically, the great number of organisms found in every case, their presence exclusively within the areas of inflammatory reaction, and their absence in 2 control brains, seem to speak in favour of such a relationship.

The clinical and pathological differences between our meningo-encephalomyelitis and "Sporadic bovine encephalomyelitis" have been emphasized in the introduction. The morphological distinction of Mycoplasmas and Chlamydia, considering the actual state of knowledge, may be somewhat problematic. Further investigations, such as improved methods of fixation for electron microscopy in clinically suspected cases, the ultrastructural examination of bovine encephalitis of known etiology (such as rabies and malignant catarrhal fever), specific microbiologic techniques, attempts to produce the disease experimentally if an agent can be isolated, have to show whether these preliminary results are valid or not.

Summary

Brain material of 7 cases of a sporadically occurring, non-purulent meningo-encephalomyelitis in Swiss cattle (Fankhauser, 1961) and 2 control brains were studied electron-microscopically. Structures interpreted as microorganisms were found in the 7 encephalitis cases, but not in the controls. They were located in the cytoplasm of endothelial and infiltrating inflammatory cells, and possibly also in an extracellular position.

The nature of these microorganisms is discussed. They seem to be non-bacterial and non-viral, and some of their morphological characteristics correspond to those of Mycoplasmas.

The question of an etiological relationship between these microorganisms and the meningo-encephalomyelitis of Swiss cattle which is clinically and morphologically distinct from "Sporadic bovine encephalomyelitis" caused by Chlamydia, is raised.

Zusammenfassung

Hirnmateriale von 7 Fällen der sporadisch auftretenden, nicht-eitrigen Meningo-Encephalomyelitis des Rindes in der Schweiz (Fankhauser, 1961) sowie Material von 2 Kontrollgehirnen wurde elektronenmikroskopisch untersucht. Gebilde, die als Mikroorganismen interpretiert wurden, fanden sich in allen 7 Encephalitisfällen, jedoch nicht in den Kontrollen. Sie lagen im Zytoplasma von endothelialen und von entzündlichen Infiltratzellen, möglicherweise auch extrazellulär.

Die Natur dieser Mikroorganismen wird diskutiert. Sie scheinen weder bakterieller noch viraler Art zu sein, und einige ihrer morphologischen Charakteristika sprechen für ihre Zugehörigkeit zu den Mykoplasmen.

Es stellt sich die Frage nach dem kausalen Zusammenhang zwischen diesen Mikroorganismen und der Rinder-Meningoencephalomyelitis in der Schweiz, die nach klinischen und pathologisch-anatomischen Gesichtspunkten von der durch Chlamydien verursachten «Sporadic bovine encephalomyelitis» verschieden zu sein scheint.

Résumé

Les cerveaux de 7 cas d'une méningo-encéphalomyélite non-purulente, sporadique des bovidés en Suisse (Fankhauser, 1961), et de deux contrôles, ont été étudiés à l'aide du microscope électronique. Des structures, interprétées comme microorganismes, ont été

trouvées dans tous les cas d'encéphalite, mais pas dans les contrôles. Elles étaient localisées dans le cytoplasme de cellules endothéliales et d'éléments infiltrants, et peut-être aussi en position extracellulaire.

La morphologie de ces éléments est discutée. Ils semblent être de nature ni bactérienne ni virale, et certaines de leurs caractéristiques les rapprochent des Mycoplasmes.

Le problème de la signification étiologique de ces organismes pour la méningo-encéphalomyélite des bovins en Suisse – maladie différente du point de vue clinique et anatomopathologique de la «Sporadic bovine encephalomyelitis» causée par des Chlamydia – est posé.

Riassunto

Sono stati studiati ultrastrutturalmente 7 casi di una meningo-encefalomielite non-purulenta e di incidenza sporadica (Fankhauser, 1961) in bovini svizzeri, e 2 casi di controllo. A livello dei focolai flogistici sono state trovate – nel citoplasma dell'endotelio, delle cellule dell'infiltrato e forse in posizione extracellulare – strutture che sono state interpretate come microorganismi.

Si discute la natura di tali microorganismi; essi sembrano essere di tipo non batterico e non virale e alcune loro caratteristiche li fanno avvicinare ai Micoplasmi.

Si discutono anche le relazioni tra tali reperti e la eziologia della meningo-encefalomielite dei bovini Svizzeri, che non ha relazioni cliniche nè morfologiche con la «Sporadic bovine encephalomyelitis» causata da Chlamydia.

Acknowledgements

The authors wish to thank Professors J. Nicolet and F. Steck, and Dr. A. Wandeler, Department of veterinary Bacteriology; Dr. G. Rossi, Miss D. Probst, Mrs. S. Weber and Mr. G. DiLullo, Department of veterinary Pathology, University of Bern, for their generous help and assistance. Special thanks are due to Prof. H. Luginbühl, Head, Department of veterinary Pathology, for the permission to work in the laboratory for Electron Microscopy.

Bibliography

- Anderson D. R.: in Hayflick L. "The Mycoplasmatales and the L-Phase of Bacteria", pp. 365–402. North-Holland Publ. Comp., Amsterdam 1969. – Anderson D. R. et al.: *J. Bacteriol.* **90**, 1387–1404 (1965). – Bagdadi M. and Martin J.: *Monatsh. Vet. Med.* **29**, 253–257 (1974). – Baskerville A. et al.: *Res. vet. Sci.* **13**, 497–499 (1972). – Billing J.: *Inaug. Diss. Tierärztl. Fak. Univ. München* 1974. – Csontos L. and Széky A.: *Nord. Vet. Med., Suppl. I*, 95–99 (1964). – Dvořák R.: *Path. Europ.* **9**, 85–103 (1974). – Fankhauser R.: *Schweiz. Arch. Tierheilk.* **103**, 225–235 (1961). – Fankhauser R.: *Schweiz. Arch. Tierheilk.* **103**, 292–302 (1961). – Fatzer R.: *Schweiz. Arch. Tierheilk.* **112**, 59–65 (1970). – Fatzer R. and Steck F.: *Schweiz. Arch. Tierheilk.* **116**, 347–356 (1974). – Frauchiger E. and Hofmann W.: *Die Nervenkrankheiten des Rindes*. Huber, Bern 1941. – Harshfield G. S.: *J.A.V.M.A.* **156**, 466–477 (1970). – Ishitani R. et al.: *Exp. Rep. 27, Govern. Exp. Stat. Anim. Hyg. (Japan)*; **II**, 59–62; **III**, 70–74 (1953). – Jasper D. et al.: *Amer. J. Vet. Res.* **30**, 521–531 (1969). – Johnston L. A. Y. et al.: *Aust. Vet. J.* **38**, 521–527 (1962). – Jubb K. V. F. and Kennedy P. C.: *Pathology of Domestic Animals*. 2nd ed., Acad. Press, New York and London 1970. – Kalmar E. et al.: *Refuah Veterinarith (Israel)*, **24**, 51–48 (1967). – Konrád J. and Boháč J.: *Vet. Časopis* **8**, 228–238 (1959). – Lomba F. et al.: *Ann. Méd. Vét.* **118**, 473–477 (1974). – Maniloff J. and Morowitz H. J.: *Bacteriol. Rev.* **36**, 263–290 (1972). – McGavin M. D.: *Aust. Vet. J.* **38**, 528–534 (1962). – Omori T. et al.: *Exp. Rep. 27, Govern. Exp. Stat. Anim. Hyg. (Japan)*; **I**, 49–54 (1953). – Omori T. et al.: *Jap. J. Exp. Med.* **24**, 257–272 (1954). – Polony R. et al.: *Vet. Časopis* **10**, 110–116 (1961). – Tully J. G.: in Hayflick L. "The Mycoplasmatales and the L-Phase of Bacteria", pp. 571–605, North-Holland Publ. Comp., Amsterdam 1969. – Tustin R. C. et al.: *J. S. Afr. vet. med. Ass.* **32**, 117–123 (1961).