

**Zeitschrift:** Schweizer Archiv für Tierheilkunde SAT : die Fachzeitschrift für Tierärztinnen und Tierärzte = Archives Suisses de Médecine Vétérinaire ASMV : la revue professionnelle des vétérinaires

**Herausgeber:** Gesellschaft Schweizer Tierärztinnen und Tierärzte

**Band:** 132 (1990)

**Heft:** 8

**Artikel:** Morphological characterisation of bovine mesothelioma

**Autor:** Stockhofe-Zurwieden, N. / Stöber, M. / Pohlenz, J.

**DOI:** <https://doi.org/10.5169/seals-593706>

### **Nutzungsbedingungen**

Die ETH-Bibliothek ist die Anbieterin der digitalisierten Zeitschriften. Sie besitzt keine Urheberrechte an den Zeitschriften und ist nicht verantwortlich für deren Inhalte. Die Rechte liegen in der Regel bei den Herausgebern beziehungsweise den externen Rechteinhabern. [Siehe Rechtliche Hinweise.](#)

### **Conditions d'utilisation**

L'ETH Library est le fournisseur des revues numérisées. Elle ne détient aucun droit d'auteur sur les revues et n'est pas responsable de leur contenu. En règle générale, les droits sont détenus par les éditeurs ou les détenteurs de droits externes. [Voir Informations légales.](#)

### **Terms of use**

The ETH Library is the provider of the digitised journals. It does not own any copyrights to the journals and is not responsible for their content. The rights usually lie with the publishers or the external rights holders. [See Legal notice.](#)

**Download PDF:** 01.04.2025

**ETH-Bibliothek Zürich, E-Periodica, <https://www.e-periodica.ch>**

intensity. For statistical evaluation an ANOVA-test with the SAS-system (software release No 148270010) was carried out.

**Results**

Group II developed hepatocellular adenomas with an overall tumor incidence of 55% (11/20). 36% of the tumor bearing animals showed multiple adenomas. The colchizine-treated group showed some intranuclear inclusion bodies. Investigation of the liver cytokeratin filaments in the DMNA group by indirect immunofluorescence showed a marked tendency towards keratinization of the liver cells with different morphologic features. This strong keratinization did not indicate any sex-dependent behavior and could be measured quantitatively in the form of a highly significant increase of the parameter HKF<sub>ind</sub> compared to the control (p < 0.001). The colchizine group did not display any structural changes compared with the control group, but image analysis of the keratin filaments revealed that the males of the colchizine group had significantly greater values for the parameter LKF<sub>ind</sub> whereas the values for the parameter HKF<sub>ind</sub> were significantly smaller than for the control males (p < 0.001). No group showed lobe-specific differences concerning the induced keratin alterations (see figure 1).

**Discussion**

In the liver cells of the DMNA-treated group a general condensation of the cytoplasmic keratin network could be observed. It was partly accompanied by both non-filamentous keratin conglomerates which were in close contact to the cytoplasmic network and with a general irregular thickening of the pericytoplasmic keratin bands with a clod-like morphology.

Thus the classical concept of Mallory body (MB) formation, the best known pathologic keratin alteration in liver cells, (6; 7; 8; 9; 11; 12; 13) has to be extended in as far that MB formation can also be a combination of keratin conglomeration which leads to polymorphic non-filamentous structures and a condensation of the cytoplasmic

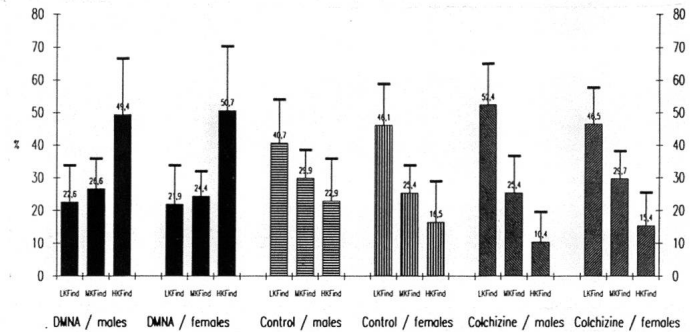


Fig. 1: Area percentage (%) of the different keratin indices of both sexes of the control, DMNA and colchizine groups

keratin network. Besides this keratinization, a general loss of keratin components can be a further expression of toxic damages of liver cells, as observed after colchizine treatment. Liver cytokeratin filaments could be morphologically and quantitatively characterized as sensitive indicators for induced liver damages.

**References**

1. Fey E. G. et al. (1884): J. Cell Biol. 98, 1973-1984. — 2. Fey E. G., Penman S. (1985): Hepatology 5, (1), 152-158. — 3. Gerace L. (1986): Trends biochem. 11, 443-446. — 4. Borenfreund E. et al. (1981): Hepatology 1, (5), 408-415. — 5. Mukunda B. R. (1987): Human Pathol. 18, (1). — 6. Christoffersen P. (1972): Acta path. microbiol. scand. Section A 80. — 7. Denk H. et al. (1979): Proc. Natl. Acad. Scie. USA 76, (8), 4112-4116. — 8. Denk H. et al. (1981): Hepatology 9-20. — 9. Denk H., Franke W. W. (1981): Europ. J. Cell Biol. 23,241-249. — 10. Kimoff R. J., Huang S. N. (1981): Lab. Invest. 45. — 11. French S. W. (1983): Pathol. Lab. Med. 107. — 12. Okanoue T.M. et al. (1985): Lab. Invest. 53, (5), 534-540. — 13. Mukunda B. R. (1987): Human Pathol. 18, (1). — 14. Uchida E. Hirono E. (1979): Gann. 70, 639-644.

Institute of Pathology, Hannover Veterinary School, FRG

**MORPHOLOGICAL CHARACTERISATION OF BOVINE MESOTHELIOMA**

N. Stockhofe-Zurwieden, M. Stöber, J. Pohlenz

Mesotheliomas are rare tumors in the bovine species with an incidence of about 1.6% (Klopfer et al., 1983). Generally they are described as diffuse tumorous proliferations on the peritoneal surface but they also occur on the pleural and pericardial serosa.

**Material and methods**

In this retrospective study 13 cases of bovine mesotheliomas of the last 16 years were re-evaluated. 10 of the 13 cases were necropsied, from 3 cases only biopsy specimens were available. The material had been fixed in 10% formalin. Paraffin-embedded tissues stained with hematoxylin-eosin were examined by light microscopy. For additional histochemical studies tissue sections were stained with Periodic-acid-Schiff (PAS) with and without diastase digestion, alcian-blue and Meyers mucicarmine. To detect ferruginous bodies sections

were stained with Turnbull-blue. Electronmicroscopical investigations were carried out in two cases on glutaraldehyde (5%) fixed tissue.

**Results**

Out of the 13 cases 5 animals were younger than 10 weeks, 3 animals between 4 months and 1 year and 5 animals were older than 5 years. The latter group consisted of cows only, whereas the first two groups included 5 males and 1 heifer.

The peritoneal cavity was predominantly affected. The tumor spread over the visceral and parietal surface of the serosa. The scrotal cavity was involved in 4 bull calves, whereas in 6 cases the pleural, pericardial and peritoneal serosa contained tumors. Macroscopically the tumors revealed a diffuse distribution pattern with some of them having a pedunculated growth and others being sessile on the surface.

The size differed from less than one cm diameter to more than ten cm with a cauliflower-like appearance.

Histologically an epithelial structure with a varying degree of connective tissue is the dominating feature but tumors with a biophasic growth pattern consisting of sarcomatous and epithelial structures also occur. Generally there is a papilliform growth often associated with tubular to adenoid configurations which were seen in several cases, especially in the adult group. Tumor cells in the adult animals appeared mainly columnar or cuboidal whereas in the calves the tumor cells had a cuboidal or often a polymorph appearance. They had vesicular nuclei with distinct to prominent eosinophilic nucleoli and especially in the polymorph cells a vacuolated cytoplasm. In the younger animals multinucleated tumor cell were frequent. Neutral and acid mucopolysaccharides in the lumen of the tubuli and intracytoplasmic were demonstrated histochemically by the PAS and PAS-diastrase stain. Ferruginous bodies as seen in human mesotheliomas were not present. The tumor cells of one adult animal revealed ultrastructurally well differentiated epithelial cells with desmosomes and tight junctions, basally located nuclei, abundant mitochondria and elongated microvilli.

*Institute of Veterinary Pathology, University of Zurich*

### IMMUNOHISTOLOGICAL STUDIES ON RABBIT HAEMORRHAGIC DISEASE (RHD)

*N. Stoercklé-Berger, B. Keller-Berger, M. Ackermann, B. Hauser, F. Ehrensperger*

RHD was first described 1984 in China. 1986 it appeared in Italy. 1988 outbreaks of RHD were observed in France, Germany, Switzerland, Eastern Europe, Spain and Portugal. 1989 the disease reached Mexico (1, 2, 3, 4, 6).

The mortality of RHD amounts about 98% in infected farms and only rabbits older than 2 months become ill.

The causative agent is supposed to be a virus: some authors isolated a Parvovirus (3, 5), closely related to Murine and Porcine Parvovirus, some others a Calicivirus or a Picornavirus (2, 4).

The diagnosis of RHD is based on clinical signs, histopathological findings in liver and kidney (1) as well as HA of liver homogenates. Furthermore the diagnosis can be verified serologically (haemagglutination inhibition test, enzyme linked immunosorbent assay) (2, 7). In the present study formalin-fixed paraffin-embedded tissue sections from rabbits were investigated for RHD using an ABC-Peroxidase method.

#### Material and methods

An ABC-Peroxidase method was performed on formalin-fixed and paraffin-embedded tissue as follows: the sections were first deparaffinized in xylene and alcohol, counterstained with haematoxylin for 1 minute and rinsed in tap water. The sections were then put in a methanol bath containing 3% H<sub>2</sub>O<sub>2</sub> for 5 minutes and washed in phosphate buffered saline (PBS) pH 8.0 for 5 minutes. The nonspecific reactions were reduced by applying normal rabbit serum, diluted 1:40 in PBS, for 1 hour in a humid chamber at room temperature. This serum was then tapped off and the slides were incubated over

#### Discussion

Mesotheliomas in calves seem to be less well-differentiated than in adults. Especially the tubular tumor structure in the adult cow requires a differential diagnosis towards adenocarcinoma (Stünzi u. Engeli, 1958). PAS-positive substances still present after diastase digestion can not exclude mesotheliomas from consideration for the final diagnosis as it is recommended for differentiation of mesotheliomas and adenocarcinomas in humans (Antman, 1986). The appearance of elongated microvilli as seen in this material may be helpful in the diagnosis (Sutton, 1988). Though ferruginous bodies were not observed a connection to asbestos exposition as is discussed pathogenetically in humans and in bovine mesotheliomas cannot be excluded (Croft, 1983).

#### References

1. Antman K. H. (1986): CRC Crit. Rev. Oncol. Hematol. 6, 287-309.
2. Croft W. (1983): Amer. Ass. Cancer Res. 24, 188.
3. Klopfer U. et al. (1983): Zbl. vet. Med. B 30, 785-788.
4. Stünzi H., Engeli P. (1958): Schweiz. Arch. Tierheilk. 100, 15-22.
5. Sutton R. H. (1988): J. Comp. Path. 99, 77-82.

night in a humid chamber at room temperature with biotinylated rabbit anti-RHD serum, diluted 1:50 in PBS. This serum was obtained from a rabbit out of a farm with RHD history which did not become ill (Institute for Viral Diseases and Immunoprophylaxis, Basel). The biotinylation was done using standard methods. The slides were then washed three times for 5 minutes in PBS. ABC (Vector Laboratories, Burlingame, California, USA) was prepared following the manufacturer's instructions and then applied on the sections and incubated for 30 minutes at 37°C. After three washes, Amino-Ethyl-Carbazole (AEC) was used as substrate to reveal antigen-antibody reaction. The slides were then rinsed in tap water and mounted in glycerol-gelatin.

Tissues from 17 rabbits were included in this study. 10 of these had been diagnosed as RHD on the basis of HA and/or histology. 4 cases were suspected and 3 cases had no history or signs of RHD. Sections of liver and kidney from all the animals as well as spleen, lymph nodes and lungs from some animals were tested.

To investigate the close relationship described between Porcine Parvovirus (PPV) and the RHD virus both blocking experiments and an ABC-Peroxidase method, similar to the RHD-ABC-Peroxidase method, were developed by the use of Swine-anti-PPV serum (Institute for Viral Diseases and Immunoprophylaxis, Basel).

#### Results

The results are summarized in Table I.

When tested for RHD, hepatocytes from infected rabbits showed intense intranuclear staining suggestive of inclusion bodies and